MO EUROPE
MY ORTHOPAEDICS
WWW.MO-JOURNAL.COM
JULY - AUGUST 2023
WAIOT
www.waiot.world

INTERVIEW


Joseph Benevenia


Carlo L. Romanò

An Artificial Intelligence (AI) interview to the President of the World Association against Infection in Orthopedics and Trauma.

MO: Good morning, Mr. President. Thank you for taking the time to speak with us today. As the President of the WAIOT, we are interested in discussing musculoskeletal infections, which are a significant concern in the field. Can you provide us with an overview of the current landscape and the challenges associated with musculoskeletal infections?

WAIOT President (W.P.): Good morning, and thank you for having me. Musculoskeletal infections indeed pose a significant challenge in the field of orthopedics and related disciplines. These infections can affect various parts of the musculoskeletal system, including bones, joints, muscles, and soft tissues. They can be caused by bacteria, fungi, or viruses, with bacteria being the most common culprits.

The challenges associated with musculoskeletal infections are multi-faceted. First and foremost, early diagnosis is crucial, as prompt intervention can help prevent severe complications. However, diagnosing these infections can be challenging because their symptoms can mimic other conditions, such as arthritis or trauma. Additionally, obtaining accurate microbial cultures can be difficult due to the presence of biofilms that protect the infecting organisms.

Treatment of musculoskeletal infections is complex and often requires a multidisciplinary approach. It typically involves a combination of surgical intervention, such as debridement or implant removal, and long-term antimicrobial therapy. However, the choice of antimicrobial agents can be complicated due to the increasing prevalence of antibiotic-resistant strains. Furthermore, managing complications such as chronic osteomyelitis or infected joint prostheses adds another layer of complexity. (Figure 1)

OVERVIEW

www.mo-journal.com/eu

The World Association against Infection in Orthopedics and Trauma (WAIOT): *Continuing the fight to the musculo-skeletal infection silent epidemic.*

As the first and the largest worldwide scientific association specifically focused on research, prevention and management of musculo-skeletal infection (MSI) and on biofilm- and implant-related infections in Orthopedic and Trauma, WAIOT is committed to raise the awareness and the knowledge in the medical scientific community about the MSI "silent epidemic", (1) causing every year millions of deaths and disabilities throughout the world.

Founded in Vienna, in May 2017 and currently with more than 2,300 members from 109 Countries, WAIOT is an open, free and inclusive scientific association, aimed at bringing together all professionals interested in MSI from all over the world. Free of charge, easy to access, open to the participation of experts from different disciplines and with a worldwide perspective, WAIOT is quite unique in the orthopedic and trauma scientific associations' panorama.

In line with the continuing cooperation between WAIOT and the MO Journal to share new insights and perspectives in the field of musculo-skeletal infections, **this Special Issue** opens with a very particular interview, that will bring us directly into the future of the **artificial intelligence** (AI), with its tremendous possibilities (and connected risks…) to change the approach to the scientific knowledge and to its dissemination.

Our travel in the world of the musculo-skeletal infections then continues in this Special Issue with a fascinating journey into how the micro-organisms live in fluids. In "**Bacteria living in biofilms in fluids: can we improve our cultural examination of synovial and other organic liquids ?**" we learn that bacteria live as well-organized communities not only when attached to solid surfaces, but also when immersed in liquids. This observation may ground the basis of a substantial **paradigm shift in microbiological analysis of liquids and eventually of semi-liquid samples**. In fact, as it already happens with physical (sonication) or chemical (dithithreitol, DTT) antibiofilm pretreatments of solid samples, it is here disclosed that chemical antibiofilm pretreatment with DTT of a biological liquid (synovial fluid) provides a significant increase in the sensitivity of cultural examination. Should this observation hold true in further studies and for other fluids, like for example urine, blood, or liquor, or semi-fluids, as feces or pus, this would lead to a complete revolution in the field of microbiology, extending antibiofilm pretreatment to all fluid samples.

The role of rare and **the difficult-to-treat pathogens** is then the focus of two papers, from **Saudi Arabia** and **Argentina** respectively, which shed some light on these highly challenging orthopedic conditions, providing an overview of the literature and some practical tips for our daily clinical activity.

Three more technical notes complete this rich MO Special Issue: the first, focusing on a novel surgical procedure, comes from the large experience of Prof. Alizadeh and his co-workers from **Azerbaijan**, that tells us **how to manage severe osteomyelitis of the calcaneus**; a second paper outlines **the Ilizarov principles in post-infection leg bone defect**, revisited from the **Egyptian perspective**, and, last, but not least, a "mise-au-point" of **the decision-making process in peri-prosthetic joint infection** is provided by Prof. J. Benevenia, the WAIOT President, and his team from the **USA**.

More about these and many other topics will be discussed at the next **WAIOT Symposia**, that will be held in Cairo (Egypt) on **November 24, 2023 at the 43rd SICOT Orthopedic World Congress**, in Rosario (Argentina) during the **33rd AAOT Congress on December 2023** and, next year, at the **3rd WAIOT International Congress**, that will be held **in Miami, FL, USA, September 12-13, 2024**

[**www.waiotcongress2024.com**]

Carlo L. Romanò,
Studio Medico Cecca-Romano – Corso Venezia, 2
20121 Milano, Italy
email: carlolucaromano@gmail.com


WAIOT
WORLD ASSOCIATION AGAINST INFECTION IN ORTHOPAEDICS AND TRAUMA
3rd WAIOT CONGRESS
"Orthopaedic and Trauma Infections: International Updates on Prevention, Diagnosis and Treatment"
September 12 - 13, 2024
Hilton Bentley | Miami, Florida
www.waiotcongress.com
www.waiot.world

MO EUROPE
MY ORTHOPAEDICS
WWW.MO-JOURNAL.COM

21, RUE DE LA RAVINELLE
F-54000 NANCY
Tel : +33 (0)9 72 21 11 73

www.mo-journal.com
abonnement@maitrise-orthopedique.com

ISSN : 2658-9877

PRINTED BY
Imprimerie moderne
www.imprimeriemoderne.pro

CREDIT PHOTO (COVER)
Copyright : shutterstock

Carlo L. Romanò

Studio Medico Associato Cecca-Romanò – Milano – Italia –
e-mail: info@carlolucaromano.com

Carlo Luca Romanò, co-founder and currently Secretary General of the World Association against Infection in Orthopedics and Trauma (W.A.I.O.T.), he is past-President of the European Bone and Joint Infection Society and co-founder and past-President of the Italian Study Group on Osteoarticular Infections.

Free consultant in orthopaedic surgery in Italy and in Albania, he served as adjunct Professor of Orthopedics at the University of Milan and has been the founder and the Director of the Center of Reconstructive Surgery and Osteoarticular Infection of the Milano Biofilm Center at the Research Orthopedic Institute Galeazzi in Milan, Italy.

Joseph Benevenia

Department of Orthopaedics - Rutgers, New Jersey Medical School - Newark – USA –
e-mail: benevejo@njms.rutgers.edu

In 2009, Dr. Benevenia was appointed as Professor and Chair in the Department of Orthopaedics at Rutgers-New Jersey Medical School. As an Orthopaedic Surgeon, he also holds appointments at Newark Beth Israel, Overlook Medical Center, Morristown Medical Center, Barnabas Medical Center, and Robert Wood Johnson Medical Center. Dr. Benevenia has trained and evaluated over 150 Orthopaedic residents and fellows, many who have been appointed as full-time professors in various subspecialties. His commitment, integrity, and ethical standards are evidenced by his ownership of 3 worldwide patents to accelerate bone healing in post-operative patients.

As a prolific researcher with over 120 peer-reviewed publications, Dr Benevenia utilizes allograft, endoprosthetic reconstructions and limb-salvage techniques to treat musculoskeletal tumors. As a renowned Orthopaedics surgeon, Dr. Benevenia presents at the annual AAOS and EMSOS meetings. Currently, he is the President of WAIOT and the Vice-Chair of the Tumors Subspecialty Committee of SICOT.

MO: How prevalent are musculoskeletal infections, and what are the common risk factors associated with them?

W.P.: Musculoskeletal infections are relatively rare compared to other types of infections. However, they can have significant consequences if not diagnosed and treated promptly. The incidence of these infections can vary depending on the specific condition and the population being studied.

Common risk factors for musculoskeletal infections include open wounds or injuries that expose the musculoskeletal system to pathogens, compromised immune system function, chronic medical conditions such as diabetes or peripheral vascular disease, intravenous drug use, recent surgery or orthopedic procedures, and the presence of prosthetic devices or implants.

MO: What are the primary symptoms and diagnostic methods used for identifying musculoskeletal infections?

W.P.: The symptoms of musculoskeletal infections can vary depending on the specific condition and the area of the body affected. However, common symptoms may include localized pain, swelling, redness, warmth, tenderness, limited range of motion, fever, chills, and overall malaise.

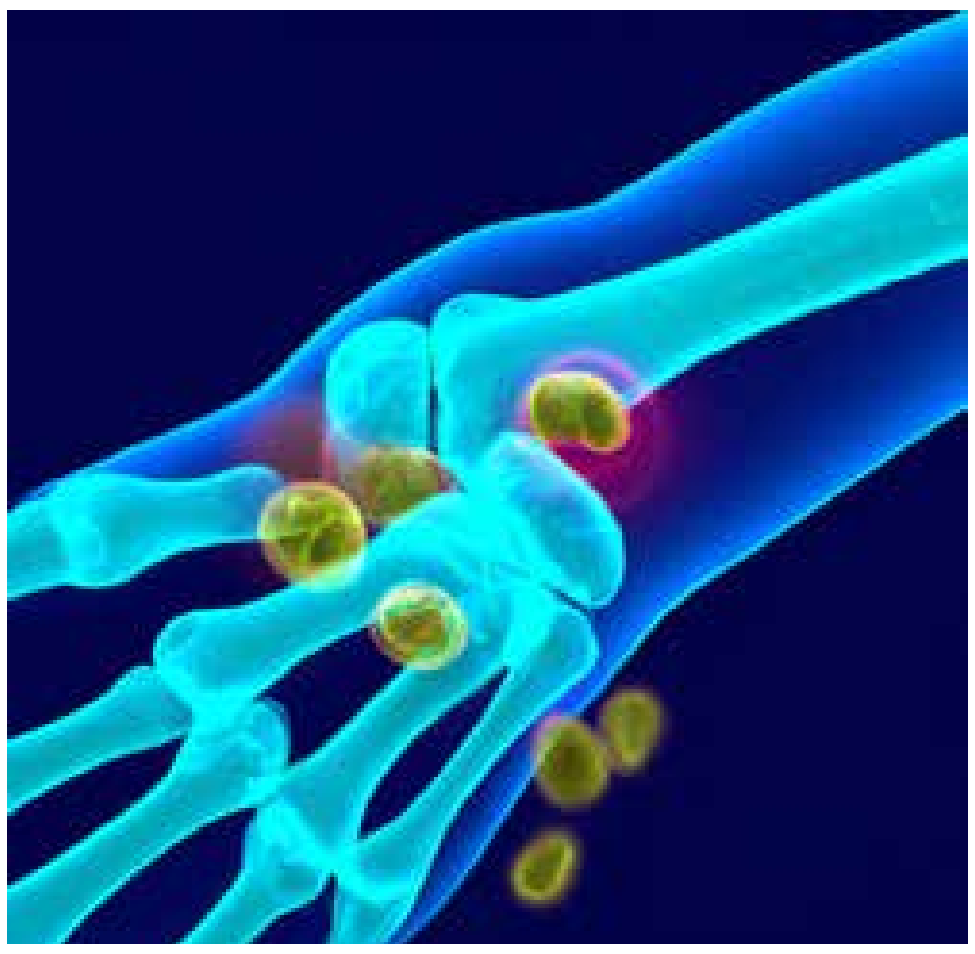

Figure 1: 3D rendering of a bone infection

To diagnose musculoskeletal infections, healthcare providers typically perform a thorough physical examination and review the patient's medical history. They may also order laboratory tests such as blood cultures, imaging studies like X-rays, magnetic resonance imaging (MRI), computed tomography (CT) scans, or ultrasound. In some cases, they might need to collect a sample of fluid or tissue from the affected area for laboratory analysis.

: How do musculoskeletal infections differ in terms of treatment approaches?

W.P.: The treatment of musculoskeletal infections depends on several factors, including the type and severity of the infection, the affected area, the patient's overall health, and the presence of any underlying conditions. In general, the goal of treatment is to eliminate the infection, relieve symptoms, and preserve the function of the musculoskeletal system.

Treatment approaches may include a combination of antibiotics, surgical intervention, drainage of abscesses, debridement (removal of infected tissue), and, in some cases, the removal of prosthetic devices or implants. Antibiotics are typically administered intravenously in severe cases or orally for less severe infections.

: Thank you for that overview. With the rising concern about antimicrobial resistance, how does this issue impact the treatment and management of musculoskeletal infections?

W.P.: Antimicrobial resistance is a global health threat that affects the management of all types of infections, including musculoskeletal infections. The emergence of multidrug-resistant organisms, such as methicillin-resistant Staphylococcus aureus (MRSA) and extended-spectrum beta-lactamase (ESBL)-producing bacteria, has complicated the treatment of musculoskeletal infections.

Treatment options become limited when the causative organisms are resistant to commonly used antibiotics. This often leads to increased hospital stays, higher healthcare costs, and a higher risk of treatment failure. It is crucial that we promote antimicrobial stewardship and encourage research to develop new antimicrobial agents and alternative treatment strategies to combat these resistant infections effectively.

: Antimicrobial stewardship is indeed a critical aspect of combating resistance. In terms of research, what recent advancements or breakthroughs have been made in the field of musculoskeletal infection management?

W.P.: Recent years have witnessed significant advancements in the field of musculoskeletal infection management. One notable area of progress is the use of biofilm-targeting strategies. Biofilms are communities of bacteria that adhere to surfaces, making them difficult to eradicate and highly resistant to antibiotics. Researchers are exploring novel approaches, such as antimicrobial peptides, anti-biofilm agents, and innovative implant coatings, to prevent and treat biofilm-associated musculoskeletal infections.

Additionally, there have been advancements in diagnostic techniques. Molecular diagnostic methods, including polymerase chain reaction (PCR) and next-generation sequencing (NGS), have enhanced our ability to rapidly identify causative organisms and detect antimicrobial resistance genes. These advancements aid in the selection of appropriate antimicrobial therapy and facilitate personalized treatment strategies.

: With the rising incidence of antibiotic-resistant strains, how is the scientific community addressing this issue and finding innovative solutions?

W.P.: The emergence of antibiotic-resistant strains has undoubtedly added a significant challenge to the treatment of musculoskeletal infections. The scientific community is actively engaged in combating this issue through various approaches. One approach is the development of new antimicrobial agents specifically targeted against resistant strains. Researchers are exploring novel compounds, including antimicrobial peptides and new classes of antibiotics, to overcome the resistance mechanisms employed by these bacteria.

Another critical aspect is optimizing the use of existing antibiotics. By promoting appropriate antibiotic stewardship, we can reduce the development of resistance and preserve the efficacy of currently available agents. This involves educating healthcare professionals about appropriate prescribing practices, emphasizing the importance of completing full courses of antibiotics, and discouraging the inappropriate use of broad-spectrum agents.

Additionally, researchers are investigating alternative treatment modalities, such as immunotherapies and phage therapy, which utilize the body's immune response or bacteriophages, respectively, to target and eliminate infecting organisms.

Collaboration between scientists, clinicians, and industry stakeholders is vital in addressing the challenge of antibiotic resistance. By fostering partnerships and promoting research, we can develop innovative solutions to combat musculoskeletal infections more effectively.

: Are there any emerging technologies or advancements that show promise in the field of musculoskeletal infection management?

W.P.: Absolutely! Several emerging technologies and advancements hold promise in the management of musculoskeletal infections. One area of interest is the development of advanced imaging techniques. Improved imaging modalities, such as molecular imaging and advanced MRI techniques, allow for better visualization of infection sites, aiding in diagnosis and treatment planning. These techniques can help identify the extent of infection, assess the response to treatment, and guide surgical interventions.

Additionally, there is growing interest in the field of biomaterials and tissue engineering for the management of musculoskeletal infections. Researchers are investigating the development of antimicrobial coatings for orthopedic implants, which can help reduce the risk of implant-associated infections. Furthermore, tissue engineering approaches aim to create bioactive scaffolds or grafts that promote tissue regeneration and simultaneously combat infections.

Another exciting area is the use of nanotechnology for targeted drug delivery. Nanoparticles can be engineered to deliver antimicrobial agents directly to the site of infection, increasing their effectiveness while minimizing systemic side effects.

These advancements, coupled with ongoing research, hold tremendous potential in improving the outcomes for patients with musculoskeletal infections. They provide hope for more effective and targeted therapies in the future.

: Those are indeed exciting advancements that offer hope for improved patient outcomes. Considering the multidisciplinary nature of musculoskeletal infection management, what role does collaboration between various specialties play in addressing this issue?

W.P.: Collaboration between various specialties is paramount in effectively addressing musculoskeletal infections. The complexity of these infections requires the expertise of different disciplines to ensure comprehensive patient care.

Orthopedic surgeons play a crucial role in diagnosing and managing the surgical aspects of these infections, including debridement and implant-related issues. Infectious disease specialists provide expertise in antimicrobial therapy, including appropriate choice, dosing, and duration of antibiotics. Microbiologists aid in identifying the pathogens and their antibiotic sensitivity.

: What advice would you give to healthcare professionals, researchers, and the general public regarding musculoskeletal infections?

W.P.: For healthcare professionals, early recognition and prompt treatment are crucial in managing musculoskeletal infections effectively. It's essential to maintain a high index of suspicion in patients with risk factors, and promptly refer them for further evaluation if an infection is suspected. Collaboration between different medical specialties, such as orthopedics, infectious diseases, and radiology, is also important in providing comprehensive care.

Researchers should continue to explore new avenues in musculoskeletal infection research, focusing on developing more accurate diagnostic tools, effective treatments, and preventive strategies. Collaboration and sharing of knowledge across institutions and countries can greatly accelerate progress in this field. For the general public, practicing good hygiene, especially in wound care and surgical incisions, can help prevent infections. It's important to promptly seek medical attention if any signs or symptoms of infection develop, particularly in individuals with underlying health conditions or recent surgeries. (Figure 2)

: Can you shed some light on the economic burden imposed by these infections?

W.P.: Musculoskeletal infections not only have significant health implications but also impose a considerable economic burden on individuals, healthcare systems, and society as a whole. The economic impact arises from various factors, including direct healthcare costs, indirect costs, and the social repercussions faced by affected individuals.

Direct healthcare costs encompass expenses related to hospitalizations, surgeries, diagnostic tests, antimicrobial therapy, and outpatient visits. Musculoskeletal infections often require prolonged treatment courses, sometimes extending over months or even years. This can result in substantial healthcare expenditures, especially when considering the cost of multiple surgeries, the need for long-term antibiotic therapy, and the management of complications. Indirect costs arise from lost productivity, work absenteeism, and disability resulting from musculoskeletal infections. These infections can severely impair an individual's ability to perform daily activities, work, or pursue their livelihoods. The extended recovery periods and potential long-term complications can lead to substantial income loss for affected individuals, negatively impacting their financial well-being.

Furthermore, there are social implications associated with musculoskeletal infections. These infections can cause physical limitations, pain, and disfigurement, affecting the quality of life and psychological well-being of patients. The burden extends to the emotional toll on families and caregivers who provide support and assistance during the treatment and recovery phases. (Figure 3)

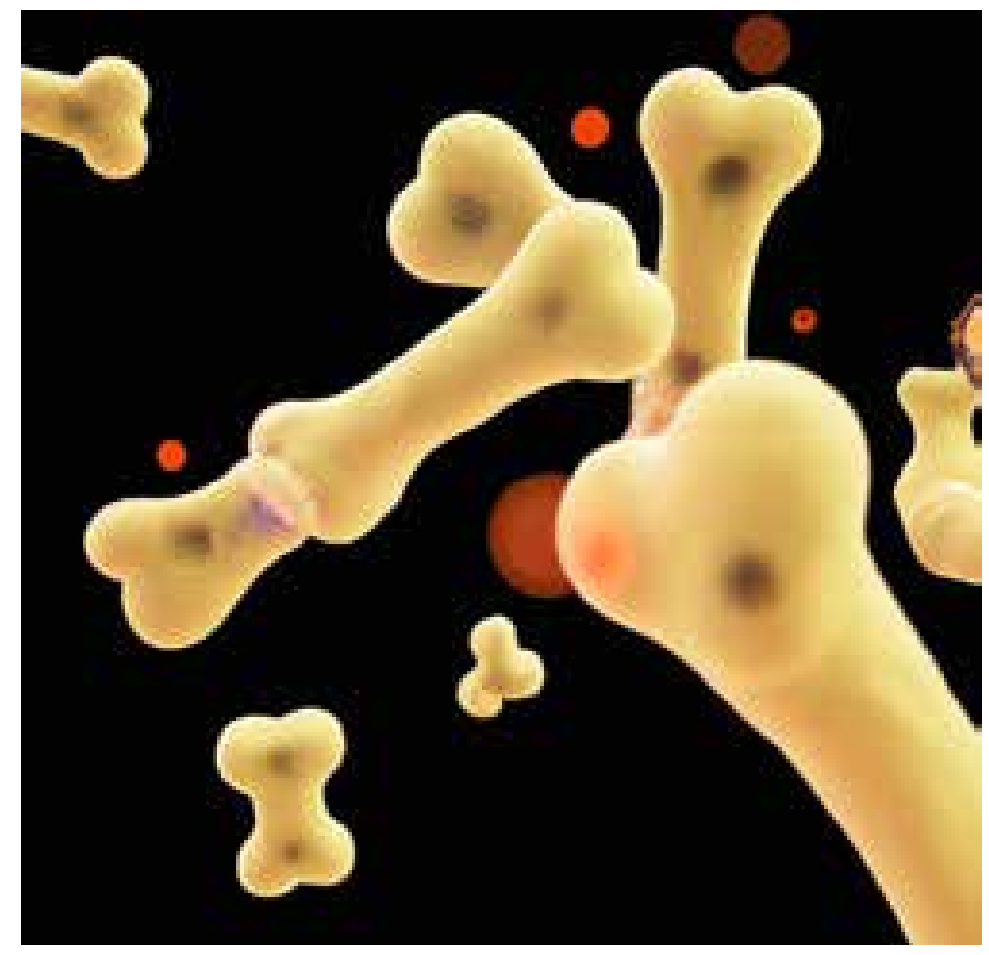

Figure 2: 3D rendering of a bone infection

: Given the significant economic and social impact of musculoskeletal infections, what measures should institutions take to allocate more resources to address this challenge effectively?

W.P.: Institutions, including governments, healthcare organizations, and research funding bodies, play a crucial role in allocating resources to address the challenges posed by musculoskeletal infections. Here are some measures that can help ensure adequate resources are available:

1. **Increased funding for research**: Institutions should prioritize funding for research dedicated to musculoskeletal infections. This includes basic science research, clinical trials, and translational studies focused on developing innovative diagnostic tools, effective treatment strategies, and preventive measures. Adequate funding will enable researchers to explore new avenues and develop novel interventions.

2. **Enhanced surveillance and data collection**: Robust surveillance systems are essential for understanding the prevalence, incidence, and burden of musculoskeletal infections. Institutions should invest in the development of comprehensive databases that can capture accurate epidemiological data. This information will help in resource planning, identifying high-risk populations, and monitoring the effectiveness of interventions.

3. **Strengthened healthcare infrastructure**: Institutions should allocate resources to improve healthcare infrastructure and capacity, particularly in regions where access to specialized care may be limited. This includes

enhancing the availability of orthopedic surgeons, infectious disease specialists, and microbiologists who are well-trained in managing musculoskeletal infections. Access to advanced imaging facilities, microbiology laboratories, and rehabilitation services should also be prioritized.

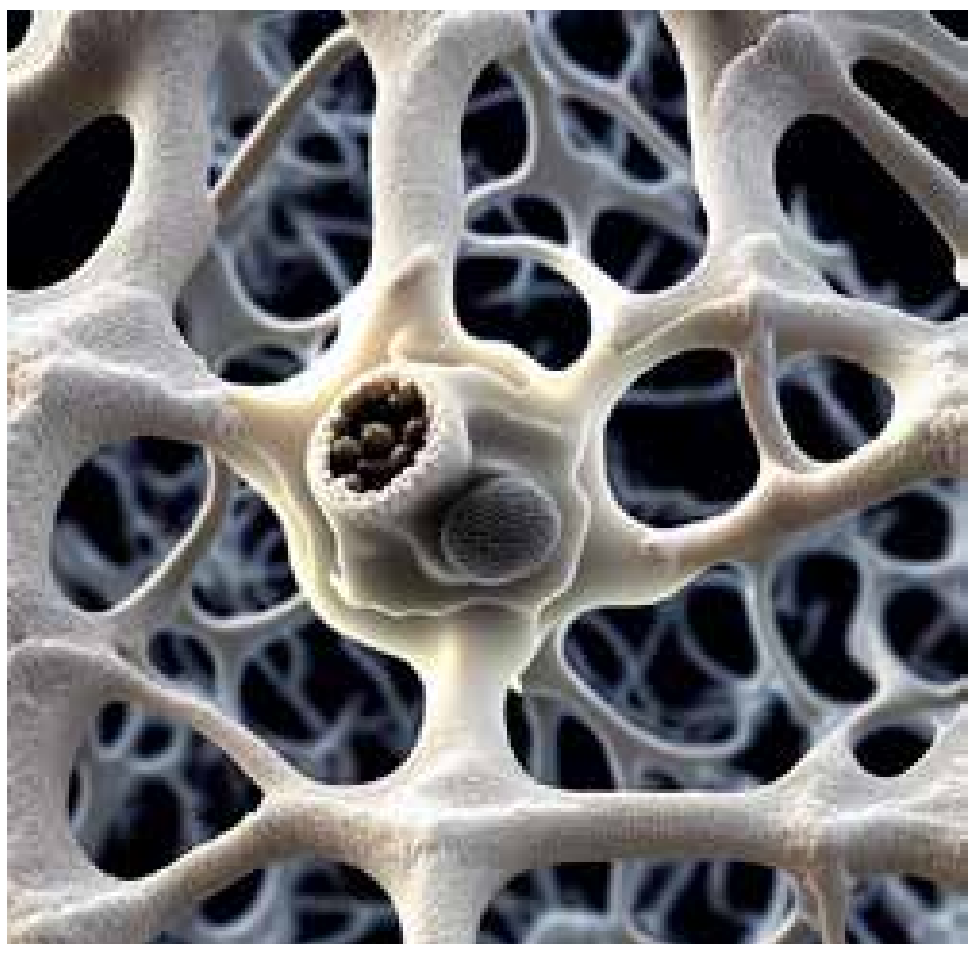

Figure 3: AI generated picture of "a femur colonized by bacteria".

4. **Education and awareness programs**: Institutions should invest in educational initiatives targeting healthcare professionals, patients, and the general public. Training programs can help healthcare professionals stay updated with the latest advancements in musculoskeletal infection management. Public awareness campaigns can educate individuals about preventive measures, early recognition of symptoms, and the importance of seeking timely medical care.

5. **Collaboration and interdisciplinary approaches**: Institutions should encourage collaboration between different specialties, such as orthopedics, infectious diseases, microbiology, and public health. This interdisciplinary approach facilitates the exchange of knowledge, fosters innovation, and ensures a comprehensive understanding of musculoskeletal infections.

By implementing these measures, institutions can better address the economic and social impact of musculoskeletal infections and improve patient outcomes.

Overall, it is crucial for institutions to recognize the significant economic and social impact of musculoskeletal infections and allocate adequate resources to research, education, multidisciplinary collaboration, and antimicrobial stewardship programs. By doing so, we can make substantial progress in improving outcomes for patients and minimizing the burden of musculoskeletal infections on individuals and society as a whole.

: Lastly, what role does WAIOT play in addressing musculoskeletal infections, and what initiatives are currently being undertaken to tackle this challenge?

W.P.: The WAIOT is committed to advancing knowledge and promoting excellence in the field of musculoskeletal infections. We play a pivotal role in fostering collaboration among researchers, clinicians, and industry partners. Our society organizes international conferences, symposia, and workshops where experts come together to share their latest research findings, discuss challenges, and explore innovative solutions. We also provide educational resources, such as webinars, online courses, and publications, to disseminate up-to-date information on the diagnosis, treatment, and prevention of musculoskeletal infections. These resources are aimed at healthcare professionals, including orthopedic surgeons, infectious disease specialists, and microbiologists, who are at the forefront of managing these infections.Furthermore, our society actively supports research in this field through grants and awards, encouraging scientists to pursue innovative studies focused on musculoskeletal infections. We also collaborate with other scientific organizations, industry partners, and governmental bodies to advocate for increased funding and attention to this critical area of research.

By promoting collaboration, education, and research, we strive to make significant contributions to the prevention, diagnosis, and treatment of musculoskeletal infections, ultimately improving patient outcomes.

: Thank you, Mr. President, for sharing your insights and highlighting the challenges and advancements and for emphasizing the need for institutions to provide more resources to address this issue. Your insights shed light on the importance of comprehensive approaches involving research, education, and collaboration to improve patient outcomes and minimize the societal burden. Your society's dedication to research, collaboration, and education is commendable. We appreciate your time and expertise today.

W.P.: Thank you for having me, and I hope our discussion contributes to raising awareness and driving positive change in the management of musculoskeletal infections. It was my pleasure to share my perspectives, and I look forward to continued efforts to address this significant healthcare challenge. ■

*****

*All the questions and answers of the interview were automatically generated by Chat_GPT4 in five different rounds through June 2023, in which the AI was requested to "**write an interview on musculoskeletal infection with the President of a scientific society in the field**" or to "**write an interview on musculoskeletal infection with the President of a scientific society in the field focusing on their economic and social impact and on the need for institutions to provide more resources**".*

*****

Human post-production was limited to put the term "WAIOT" where the AI did mention the "scientific society XXX" and to perform a minimal re-assembly of the questions and answers across the five interviews, in order to avoid repetitions. All the interviews were in fact stand—alone and were different both in the type and the format of the questions and answers that were generated by the artificial intelligence.

Images throughout the text were generated by the respective AI platforms, under the command reported in the legend of each picture.

*****

The World Association against Infection in Orthopedics and Trauma is committed to explore the limits and to take advantage of the new and effective applications of the Artificial Intelligence in the field of musculoskeletal infections.

*Anyone interested in this research may contact Dr. Carlo L. Romanò at **ai@waiot-world**.*

*****

Acknowledgement: Carlo L. Romanò, the virtual "Interviewer" thanks the real W.A.I.O.T.

President, Prof. Joseph Benevenia, for accepting to be for a while embodied by his virtual avatar…

BACTERIA LIVING IN BIOFILMS IN FLUIDS: CAN WE IMPROVE OUR CULTURAL EXAMINATION OF SYNOVIAL AND OTHER ORGANIC LIQUIDS ?

Alessio GIANNETTI[1,2], Andrea FIDANZA[1,3], Carlo Luca ROMANÒ[4], Giandomenico LA-GROSCINO[1], Alessio CIUFFOLETTI[2], Costantino ROSSI[3], Thami BENZAKOUR[5], Hazem ALKHAWASHKI[6], Guenter LOB[7], Andreas MAVROGENIS[8], Konstantinos TSIKOPOULOS[9], Lorenzo DRAGO[10]

1. Mininvasive Orthopaedic surgery - Department of life, Health & Environmental Sciences. University of L'Aquila, L'Aquila, Italy.
2. Unit of Orthopaedics and Traumatology, "G. Mazzini" Hospital, Teramo (Te), Italy
3. Unit of Orthopaedics and Traumatology, "SS Filippo e Nicola" Hospital, Avezzano (Aq), Italy
4. Studio Medico Associato Cecca-Romanò, Corso Venezia 2, 20121 Milan, Italy
5. Zerktouni Ortho Clinic, Casablanca, Morocco
6. Advanced Medical Center, Riyadh 12482, Saudi Arabia.
7. University of Munich, Emeritus Professor, Head of department of Traumatology, Germany
8. First Department of Orthopaedics, National and Kapodistrian University of Athens, School of Medicine, Athens, Greece
9. First Department of Pharmacology, School of Medicine, Faculty of Health Sciences, Aristotle University of post code Thessaloniki, Thessaloniki, Greece
10. Laboratory of Clinical Microbiology and Microbiome Unit, Department of Biomedical Sciences for Health, University of Milan, Italy - lorenzo.drago@unimi.it

INTRODUCTION

Microorganisms are often considered as freely suspended cells, defined as planktonic, and classified on their growth characteristics in a culture media. However, Antonie Philips van Leeuwenhoek, already in the seventeenth century described the existence of surface-associated microorganisms, growing and living in communities. Biofilms-embedded microorganisms show typical mechanisms for initial attachment to a surface, development of a community structure, and detachment [1].

A biofilm is an assemblage of microbial cells, associated together on a surface and enclosed in a matrix of primarily polysaccharide material, living like in a proper ecosystem. Depending on the environment in which the biofilm is formed, non-cellular materials such as mineral crystals, clay and silt particles, corrosion particles, and blood components may also be present in the biofilm matrix. Organisms associated with biofilms also differ from planktonic with respect to transcribed genes. Within the ecosystem of the biofilm, bacteria have developed a communication system called "Quorum sensing", which allows them to coordinate their behavior using chemical molecules as signals. Quorum sensing communication system allows the microorganisms to orchestrate the group behavior, resulting in maximum benefit for the whole bacteria population living in the biofilm. [2]

As the knowledge of biofilms improved, it become more and more evident in the last decades that this is the predominant lifestyle of bacteria and fungi and an example of an extremely successful physiological adaptation, as they thrive in most natural environments as well as in harsh conditions.

Unfortunately, biofilms are also often associated with the majority of human infectious diseases and can negatively impact health. Indeed, biofilms offer to microorganisms an enormous capacity to resist host immune system defenses and antimicrobial therapy. In healthcare environments, the persistence of the microorganisms is extended by the formation of biofilms, being responsible for the onset and spread of hospital-care-associated infections (HCAIs) (also referred to as "nosocomial" or "hospital acquired" infections). HCAIs can result in prolonged hospital stays, long-term disabilities, enhanced resistance of the microorganisms to antimicrobials, enormous additional costs for the health care systems, the patients and their families, and increased mortality rates. The prevalence of HCAI is estimated to be between 5.7% and 19.1%.

According to some estimates, 65–80% of total human infections are associated with biofilm formation and include: periodontitis/dental caries, cystic fibrosis lung infection, chronic otitis media, infective endocarditis, chronic osteomyelitis, chronic rhinosinusitis, chronic tonsillitis, chronic peritonitis, chronic prostatitis, chronic wounds, recurrent urinary tract infections (UTIs), bloodstream infections (BSIs), ventilated-associated pneumonia and infections associated with indwelling medical devices (e.g., contact lenses, heart valves, joint prostheses, and other orthopedic implants, intrauterine devices, intravascular catheters, urinary tract catheters, peritoneal catheters, etc.) [3]

In humans, bacterial and fungal biofilms may form on a wide variety of surfaces, including living tissues, foreign bodies and biomaterials; the solid-liquid interface between a surface and an aqueous medium (e.g., water, blood) provides an ideal environment for the attachment and growth of microorganisms. The spreading of the biofilm on a surface is made possible by dispersion, a process through which bacterial cells leave the biofilms, return to an independent planktonic lifestyle and eventually colonize new surfaces to establish new biofilm-based communities. [4]

Recently, the ability of bacteria to form biofilms in fluids, like synovial fluid, blood, urine, cerebrospinal fluids, has been reported. Biofilm formation in liquids proceeds through an initial adhesion process of bacterial cells one to the other, by forming an extracellular polymeric substance, that provides a three-dimensional structure for the bacterial cell's aggregates, protecting them from the external environment. [5]

Aim of this article is to provide an overview of the bacteria living in human fluids, with a focus on the associated pathologic conditions and the impact that this phenomenon may have on the cultural examination of fluid samples.

SYNOVIAL FLUID

Periprosthetic joint infections (PJIs) represent a great challenge for the patients and the healthcare systems, due to the increased length of hospital stay, need for complex and expensive surgeries and prolonged antibiotic treatments. [6,7] Recently, the presence of bacteria and biofilm aggregates floating in the synovial fluids of PJIs has been reported and associated to the resistance of bacterial joint infections to common treatments [8-9]. The ability of bacteria to live in biofilm aggregates may explain the limited efficacy of current microbiological investigations of synovial fluids, with reported sensitivities as low as 41.6 to 90% [10-11]. Moreover, the formation of fluctuating biofilm aggregates may compromise the ability of antibiotics to reach and kill the microbial cells, as it happens in bacteria living in biofilms adhering on a surface. Furthermore, the bacterial-protein interactions in these aggregates changes the production of virulence factors and the phenotype, inducing a marked tolerance to antibiotics [12]. Bacteria living in synovial fluids of PJI may substantially contribute to the development of a chronic condition difficult to diagnose and to reat and thus requiring suitable antibiofilm strategies.

URINARY TRACT

Urinary tract infections (UTIs), one of the most common infections sustained by bacteria, represents a severe public health issue. The operating costs of these infections are estimated around US$3.5 billion per year in the US. UTIs may manifest in different forms such as cystitis, pyelonephritis, prostatitis, urethritis. Ideal environment for attachment and colonization by uropathogens are urinary catheters. The most common agents responsible for complicated UTIs are Escherichia coli, Enterococcus spp., Klebsiella pneumoniae, Candida spp., Staphylococcus aureus, Proteus mirabilis and Pseudomonas aeruginosa. All these microorganisms have already been linked to biofilm formation [13]. Large fragments of the biofilms and high concentrations of microbial cells can detach from the catheter and flow into the bladder spreading the infection and leading to bacteriuria. In addition, uropathogens can form biofilm in the bladder and kidney, reducing antibiotic susceptibility and causing recurrent infections. Biofilms play a central role in catheter associated UTIs especially in patients with prolonged catheterization, leading to increased morbidity and mortality [14]. Bacterial populations living in biofilms show a more efficient and adapted behavior, compared to planktonic bacteria, with improved chance of survival while the biofilm community sheds planktonic cells able to further colonize adjacent tissues [15].

BLOOD SYSTEM

Not less relevant and worrying than UTIs are the blood system infections (BSIs), ranked as the 12th cause of death in the USA, with the estimated mortality rate of 15–30%. Through the bloodstream microorganism can spread from a local infection (endocarditis, meningitis, osteomyelitis...) to distant sites. In addition, intravenous catheters are an important risk factor for BSIs. In fact, bacterial biofilm can easily develop on the surface of this devices, and biofilm fragments or planktonic microorganism may spread into the bloodstream. The most often isolated pathogens in bacteremia are *S. aureus, E. coli, K. pneuomoniae, P. aeruginosa, Enterococcus faecalis, Staphylococcus epidermidis, Enterobacter cloacae, Streptococcus pneumoniae, Enterococus faecium and Acinetobacter baumannii* [15-17]: all well-known biofilm-producers. As it happens with cultural examination in other fluids, blood cultures may often result in false negative findings.

Cerebrospinal fluid (CSF)

Thousands of CSF shunts are implanted every year as a treatment of hydrocephalus. To relieve cranial pressure in fact, CSF is generally shunted, from the cerebral ventricle into the peritoneal cavity. Common complications of this procedure are intraventricular hemorrhage, obstruction, over drainage of CSF and infection. Clinical signs range from local manifestations as ventriculitis, peritonitis, to nephritis or septicemia, leading to high risk of seizures, decreased intellectual performance, and mortality [18]. Correct diagnosis and treatment of device-related infections are notoriously difficult, because of bacteria forming biofilms. Diagnostic cultures of fluid aspirates and swabs are often falsely negative, presumably because of the very low chance to find cells in the planktonic state. [19,20].

SALIVA

Van Leeuwenhoek, simply using his microscope, observed for the first-time microorganisms on tooth surfaces, the dental plaque [1]. Saliva under normal circumstances is sterile until it leaves the salivary duct and enters the oral cavity, where it is quickly contaminated by biofilm-producer microorganisms. Bacterial growth in the form of biofilm has been associated with most ear, nose, and throat infections [21]. Implanted biomaterials and other inert surfaces with poor host defense, such as salivary calculi, are subject to bacterial attachment and biofilm formation and also in this environment, pharmaceutical treatment and immune system have limited effect on bacteria living in biofilm. Biofilm growth has been associated with chronic otitis media and mastoiditis as well as chronic infections of the adenoid tissue. Planktonic bacteria may shed from mature biofilm and being the cause of an acute phase of infection such as a chronic and recurrent otitis media. Furthermore, the microbial diagnostics in oral cavity are always complicated as the saliva in mouth is contaminated with the oral microbiome [21, 22], which currently form large amount of biofilms.

TRACHEAL ASPIRATE

Nosocomial pneumonia represents about one quarter of all nosocomial infections and represents the first cause of nosocomial infection in Intensive care unit, contributing to extend the length of hospitalization, mortality and costs of treatment. Tracheal intubation in patient under mechanic ventilation in fact, increases the risk for infection ranging from six to twenty times higher. Bacteriological diagnosis through specific specimen brush, bronchoalveolar lavage, and endotracheal aspirates have been nowadays standardized but lack of specificity, as it is based on the identification of bacteria growing in tracheal secretion. It is necessary to consider that in ventilator-associated pneumonia biofilm plays an important role in the diagnosis as in the treatment. The endotracheal tube allows direct entry of microbial colonization of dental plaque and oropharynx, that has natural ability to form biofilm, into the lower respiratory tract. Then, bacteria within the biofilm can infect the lungs by several ways: through detachment of biofilm portions that then reaches the lungs and by aspiration into deeper airways of aerosolized planktonic pathogens detached from the biofilm [23,24].

DRAINS

In a wide variety of surgical specialties, closed suction drains are used for prevention of haematoma and fluid accumulation. Nevertheless, more and more evidence, in different surgical field are showing that not always drains are effective, instead they are unnecessary or counterproductive, encouraging local wound complications and infections [25]. A recent in vivo drain study demonstrated a significant biofilm formation, as soon as two hours after drain insertion, cocci within clumps of fibrin adherent to the surface of the drain were detected. This finding suggests that drains are contaminated very early, and considering the ideal culture medium that clotted blood represents, combined with a foreign body in the form of the drain, biofilm formation is obviously able to evolve very rapidly [26]. In matter of prevention, even for this reason the drains should be used for the shortest time and if possible no later than 24 hours under strict surveillance.

IS IT POSSIBLE TO DETACH BACTERIA IN FLUIDS FROM THEIR BIOFILMS? DITHIOTHREITOL (DTT) AS A DIAGNOSTIC TOOL

The presence of biofilm-bacterial aggregates may have a strong impact on pathogen identification, on the bacterial count and antibiogram evaluation performed with traditional cultural techniques, that were designed for planktonic, isolated microorganisms (Figure 1). While physical (sonication) and chemical (Dithiothreitol, DTT) systems have been proposed to dislodge bacteria adhering on a surface from their biofilms, less is known about the possibility to improve microbiological sensitivity by antibiofilm pre-treatment of fluid samples. In fact, to the best of our knowledge, only DTT has been tested to dislodge bacteria from their biofilms in synovial fluid samples with promising results.
As DTT has been demonstrated to be able to release microorganisms from the biofilm produced on prosthetic implants and on human tissues, it has also recently been demonstrated to be effective in disrupting biofilm-bacteria aggregates in fluids, and more specifically it has been shown to be effective in the synovial fluid [5] (Figure 2). DTT is a chemical agent that reduces disulfide bonds in peptides and can indeed alter the matrix of biofilm releasing bacteria without affecting their viability. Through this procedure, bacterial culture is possible and so identification and antibiotic susceptibility tests are easier to perform [27-30].

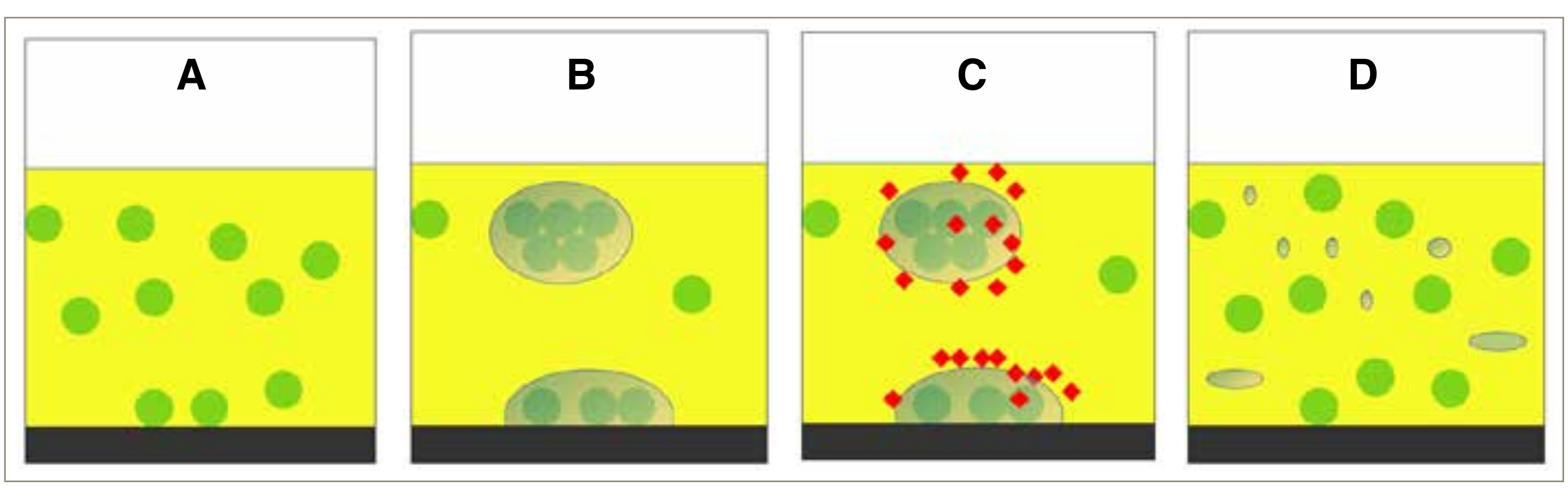

Figure 1: Schematic representation of (A) planktonic bacteria (green circles) floating free in a fluid and adhering on a surface; (B) after few hours, the microorganisms aggregate in biofilms both on the surface and in the fluid; (C) the application of a chemical antibiofilm agent (e.g. dithiothreitol, DTT) (red diamonds) breaks the biofilm, without killing the bacteria, that (D) may hence return free to float in the surrounding fluid. Biofilm remnants can be found in the fluid. Free living bacteria may then easily be cultured and/or analyzed with molecular methods with increased sensitivity.

Figure 2 shows a the last generation of a completely closed system and procedure for chemical antibiofilm pretreatment of solid and liquid biological samples with dithiothreitol (DTT).

CONCLUSION

Diagnosis for biofilm-associated infection (BAI) can be challenging, and even with the correct diagnosis, therapy can be particularly difficult, long and expensive. The fact that bacteria may live in biofilms even in fluid should be taken into account both as to concern our diagnostic and treatment approach. In particular, as to concern microbiological diagnosis, the spontaneous tendency of many bacterial species to aggregate must be considered. In fact, cell disaggregation is often omitted when analyzing bacterial samples and the number of Colony Forming Units (CFUs) is usually taken as the golden standard. However, the CFU count is not an absolute measure of bacteria cells; instead, it represents the number of colonies that can form on an agar plate from a given sample. If bacteria aggregates are cultured as a single cell, the CFU will be falsely low and even false negative results may be reported.

Molecular approaches may at least partially overcome this difficulty; nevertheless, their use is limited due to high costs of the procedure, the level of expertise required and the inability to differentiate living from dead microroganisms. Antibiofilm chemical pre-treatment of fluid samples using DTT can be a low-cost and simple-to-use alternative in BAIs, and probably it should be included as a routine not only for any solid or tissue biological sample but also for the liquid ones. In fact, as antibiofilm pre-treatment of synovial fluid with DTT has been shown to increase the sensitivity of cultural examination by freeing the microorganisms from the biofilm aggregates, it may be expected that a similar result could be obtained by applying the same system to other fluids such as saliva, urine, blood, and cerebrospinal liquid, paving the way to a complete change in the results of the microbiological examinations. Given the high social and economic costs of chronic biofilm-related infections in nearly all the fields of Medicine, we believe that more research on this subject would be greatly beneficial. ■

Bibliography

[1] **Donlan RM. Biofilms: microbial life on surfaces.** Emerg Infect Dis. 2002 Sep;8(9):881-90. doi: 10.3201/eid0809.020063.

[2] **Xie H, Cook GS, Costerton JW, Bruce G, Rose TM, Lamont RJ. Intergeneric communication in dental plaque biofilms.** J Bacteriol. 2000 Dec;182(24):7067-9. doi: 10.1128/JB.182.24.7067-7069.2000.

[3] **Pinto H, Simões M, Borges A. Prevalence and Impact of Biofilms on Bloodstream and Urinary Tract Infections: A Systematic Review and Meta-Analysis.** Antibiotics (Basel). 2021 Jul 8;10(7):825. doi: 10.3390/antibiotics10070825.

[4] **Singh PK, Bartalomej S, Hartmann R, Jeckel H, Vidakovic L, Nadell CD, Drescher K. Vibrio cholerae Combines Individual and Collective Sensing to Trigger Biofilm Dispersal.** Curr Biol. 2017 Nov 6;27(21):3359-3366.e7. doi: 10.1016/j.cub.2017.09.041. Epub 2017 Oct 19.

[5] **Drago L, Romanò D, Fidanza A, Giannetti A, Erasmo R, Mavrogenis AF, Romanò CL. Dithiotreitol pre-treatment of synovial fluid samples improves microbiological counts in peri-prosthetic joint infection.** Int Orthop. 2023 May;47(5):1147-1152. doi: 10.1007/s00264-023-05714-z. Epub 2023 Feb 22.

[6] **Parisi TJ, Konopka JF, Bedair HS. What is the Long-term Economic Societal Effect of Periprosthetic Infections After THA? A Markov Analysis.** Clin Orthop Relat Res. 2017 Jul;475(7):1891-1900. doi: 10.1007/s11999-017-5333-6. Epub 2017 Apr 7.

[7] **Ghirardelli S, Touloupakis G, Antonini G, Violante B, Fidanza A, Indelli PF. Debridement, antibiotic, pearls, irrigation and retention of the implant and other local strategies on hip periprosthetic joint infections.** Minerva Orthop 2022;73:409-15. doi: 10.23736/S2784-8469.21.04173-0

[8] **Dastgheyb SS, Hammoud S, Ketonis C, Liu AY, Fitzgerald K, Parvizi J, Purtill J, Ciccotti M, Shapiro IM, Otto M, Hickok NJ. Staphylococcal persistence due to biofilm formation in synovial fluid containing prophylactic cefazolin.** Antimicrob Agents Chemother. 2015 Apr;59(4):2122-8. doi: 10.1128/AAC.04579-14. Epub 2015 Jan 26.

[9] **Perez K, Patel R. Biofilm-like aggregation of Staphylococcus epidermidis in synovial fluid.** J Infect Dis. 2015 Jul 15;212(2):335-6. doi: 10.1093/infdis/jiv096. Epub 2015 Feb 23.

[10] **Tande AJ, Patel R. Prosthetic joint infection.** Clin Microbiol Rev. 2014 Apr;27(2):302-45. doi: 10.1128/CMR.00111-13.

[11] **Leggett A, Li DW, Bruschweiler-Li L, Sullivan A, Stoodley P, Brüschweiler R. Differential metabolism between biofilm and suspended Pseudomonas aeruginosa cultures in bovine synovial fluid by 2D NMR-based metabolomics.** Sci Rep. 2022 Oct 15;12(1):17317. doi: 10.1038/s41598-022-22127-x.

[12] **Pestrak MJ, Gupta TT, Dusane DH, Guzior DV, Staats A, Harro J, Horswill AR, Stoodley P. Investigation of synovial fluid induced Staphylococcus aureus aggregate development and its impact on surface attachment and biofilm formation.** PLoS One. 2020 Apr 17;15(4):e0231791. doi: 10.1371/journal.pone.0231791. Erratum in: PLoS One. 2020 May 14;15(5):e0233534.

[13] **Pelling H, Nzakizwanayo J, Milo S, Denham EL, MacFarlane WM, Bock LJ, Sutton JM, Jones BV. Bacterial biofilm formation on indwelling urethral catheters.** Lett Appl Microbiol. 2019 Apr;68(4):277-293. doi: 10.1111/lam.13144.

[14] **Wasfi R, Hamed SM, Amer MA, Fahmy LI. Proteus mirabilis Biofilm: Development and Therapeutic Strategies.** Front Cell Infect Microbiol. 2020 Aug 14;10:414. doi: 10.3389/fcimb.2020.00414.

[15] **Pinto H, Simões M, Borges A. Prevalence and Impact of Biofilms on Bloodstream and Urinary Tract Infections: A Systematic Review and Meta-Analysis.** Antibiotics (Basel). 2021 Jul 8;10(7):825. doi: 10.3390/antibiotics10070825.

[16] **Diekema DJ, Hsueh PR, Mendes RE, Pfaller MA, Rolston KV, Sader HS, Jones RN. The Microbiology of Bloodstream Infection: 20-Year Trends from the SENTRY Antimicrobial Surveillance Program.** Antimicrob Agents Chemother. 2019 Jun 24;63(7):e00355-19. doi: 10.1128/AAC.00355-19.

[17] **Hattori H, Maeda M, Nagatomo Y, Takuma T, Niki Y, Naito Y, Sasaki T, Ishino K. Epidemiology and risk factors for mortality in bloodstream infections: A single-center retrospective study in Japan.** Am J Infect Control. 2018 Dec;46(12):e75-e79. doi: 10.1016/j.ajic.2018.06.019.

[18] **Mounier R, Kapandji N, Birnbaum R, Cook F, Rodriguez C, Nebbad B, Lobo D, Dhonneur G. Biofilm-associated infection: the hidden face of cerebrospinal fluid shunt malfunction.** Acta Neurochir (Wien). 2016 Dec;158(12):2321-2324. doi: 10.1007/s00701-016-2977-z.

[19] **Fux CA, Quigley M, Worel AM, Post C, Zimmerli S, Ehrlich G, Veeh RH. Biofilm-related infections of cerebrospinal fluid shunts.** Clin Microbiol Infect. 2006 Apr;12(4):331-7. doi: 10.1111/j.1469-0691.2006.01361.x.

[20] **Benachinmardi KK, Ravikumar R, Indiradevi B. Role of Biofilm in Cerebrospinal Fluid Shunt Infections: A Study at Tertiary Neurocare Center from South India.** J Neurosci Rural Pract. 2017 Jul-Sep;8(3):335-341. doi: 10.4103/jnrp.jnrp_22_17.

[21] **Perez-Tanoira R, Aarnisalo A, Haapaniemi A, Saarinen R, Kuusela P, Kinnari TJ. Bacterial biofilm in salivary stones.** Eur Arch Otorhinolaryngol. 2019 Jun;276(6):1815-1822. doi: 10.1007/s00405-019-05445-1. Epub 2019 Apr 26.

[22] **Simon-Soro A, Ren Z, Krom BP, Hoogenkamp MA, Cabello-Yeves PJ, Daniel SG, Bittinger K, Tomas I, Koo H, Mira A. Polymicrobial Aggregates in Human Saliva Build the Oral Biofilm.** mBio. 2022 Feb 22;13(1):e0013122. doi: 10.1128/mbio.00131-22. Epub 2022 Feb 22.

[23] **Ferreira Tde O, Koto RY, Leite GF, Klautau GB, Nigro S, Silva CB, Souza AP, Mimica MJ, Cesar RG, Salles MJ. Microbial investigation of biofilms recovered from endotracheal tubes using sonication in intensive care unit pediatric patients.** Braz J Infect Dis. 2016 Sep-Oct;20(5):468-75. doi: 10.1016/j.bjid.2016.07.003. Epub 2016 Aug 8.

[24] **Souza LCD, Mota VBRD, Carvalho AVDSZ, Corrêa RDGCF, Libério SA, Lopes FF. Association between pathogens from tracheal aspirate and oral biofilm of patients on mechanical ventilation.** Braz Oral Res. 2017 Jun 5;31:e38. doi: 10.1590/1807-3107BOR-2017.vol31.0038.

[25] **Dower R, Turner ML. Pilot study of timing of biofilm formation on closed suction wound drains.** Plast Reconstr Surg. 2012 Nov;130(5):1141-1146. doi: 10.1097/PRS.0b013e318267d54e.

[26] **De Waele JJ, Boelens J, Van De Putte D, Huis In 't Veld D, Coenye T. The Role of Abdominal Drain Cultures in Managing Abdominal Infections.** Antibiotics (Basel). 2022 May 20;11(5):697. doi: 10.3390/antibiotics11050697.

[27] **Giannetti A, Romano J, Fidanza A, Di Mauro M, Brunetti M, Fascione F, Calvisi V (2022) The diagnostic potential of Micro- DTTect compared to conventional culture of tissue samples in orthopedic infections.** Lo Scalpello J 36:111–115. https://doi.org/ 10.36149/0390-5276-262.

[28] **De Vecchi E, Bortolin M, Signori V, Romanò CL, Drago L. Treatment With Dithiothreitol Improves Bacterial Recovery From Tissue Samples in Osteoarticular and Joint Infections.** J Arthroplasty. 2016 Dec;31(12):2867-2870. doi: 10.1016/j.arth.2016.05.008. Epub 2016 May 11.

[29] **Calori GM, Colombo M, Navone P, Nobile M, Auxilia F, Toscano M, Drago L. Comparative evaluation of MicroDTTect device and flocked swabs in the diagnosis of prosthetic and orthopaedic infections.** Injury. 2016 Oct;47 Suppl 4:S17-S21. doi: 10.1016/j.injury.2016.07.040.

[30] **Sambri A, Cadossi M, Giannini S, Pignatti G, Marcacci M, Neri MP, Maso A, Storni E, Gamberini S, Naldi S, Torri A, Zannoli S, Tassinari M, Fantini M, Bianchi G, Donati D, Sambri V. Is Treatment With Dithiothreitol More Effective Than Sonication for the Diagnosis of Prosthetic Joint Infection?** Clin Orthop Relat Res. 2018 Jan;476(1):137-145. doi:10.1007/s11999.0000000000000060.

APPROACHES IN SURGICAL TREATMENT OF FUNGAL PROSTHETIC JOINT INFECTION

A REVIEW OF CURRENT KNOWLEDGE AND PRACTICAL RECOMMENDATIONS

Hazem ALKHAWASHKI[1], Carlo Luca ROMANO[2], Heinz WINKLER[3], Joseph BENEVENIA[4], Lorenzo DRAGO[5], Thami BENZAKOUR[6], Guenter LOB[7]

1. Advanced Medical Center, Riyadh Saudi Arabia - bonedoc57@gmail.com
2. Studio Medico Cecca-Romanò, Milano, Italy.
3. Osteitis Center Döbling, Döbling Private Hospital, Vienna, Austria
4. Rutgers- New Jersey Medical School, Newark, NJ
5. Department of Biomedical Sciences for Health, University of Milan, 20100 Milano, Italy
6. Zerktouni Orthopaedic Clinic - Casablanca, Morocco
7. Section Injury Prevention, DGOU, Berlin, Germany

INTRODUCTION

Among the many thousands of species of fungi, about a 100-cause infection in h umans [1]. Fungal infections are not readily recognized and do not advertise their presence and are not easy to demonstrate [2,3]. Fungal arthritis has a worldwide distribution with prevalence ranging from 0.4% to 20%, is more in men and usually presents as oligoarthritic [2]. Fungal prosthetic joint infection (fPJI) ranges between 0.6-2% [4,5]. Bone and joint fungal infection may result from direct inoculation, contiguous spread, or hematogenous seeding, which is the most common, and more commonly causes osteomyelitis than septic arthritis. [1,6,7]. There are conflicting reports on the common age and commonest sex affected by fPJI, with a range between 52 and 85 years and some reports of male predominance and others of female predominance [5,8,9].

The course of fPJI is both insidious and indolent. Clinical symptoms and signs are variable, but pain, swelling and sinus tract are the most common, and are reported in 75-100%, 25-73% and 0-80% of cases respectively [4,5,9,10]. Other variable presentations are low grade fever, reduced range of motion, warmth, and redness. There is poor evidence in literature regarding the management of fPJI and the main guidelines are based on case reports, case series, reviews, and expert opinion [4,5,11-14]. Other sources are the consensus of opinions at different infection societies. We have reviewed the literature and the available knowledge (PubMed, Google Scholar, Orth Evidence, book chapters and infection societies consensus) and came out with recommendations based on the best consistency opinion of experts and infection societies [15-18].

RESULTS

Fungal PJI is most commonly caused by the Candida Albicans and non -Albicans species (50-80%), followed by Aspergillus [19-22].

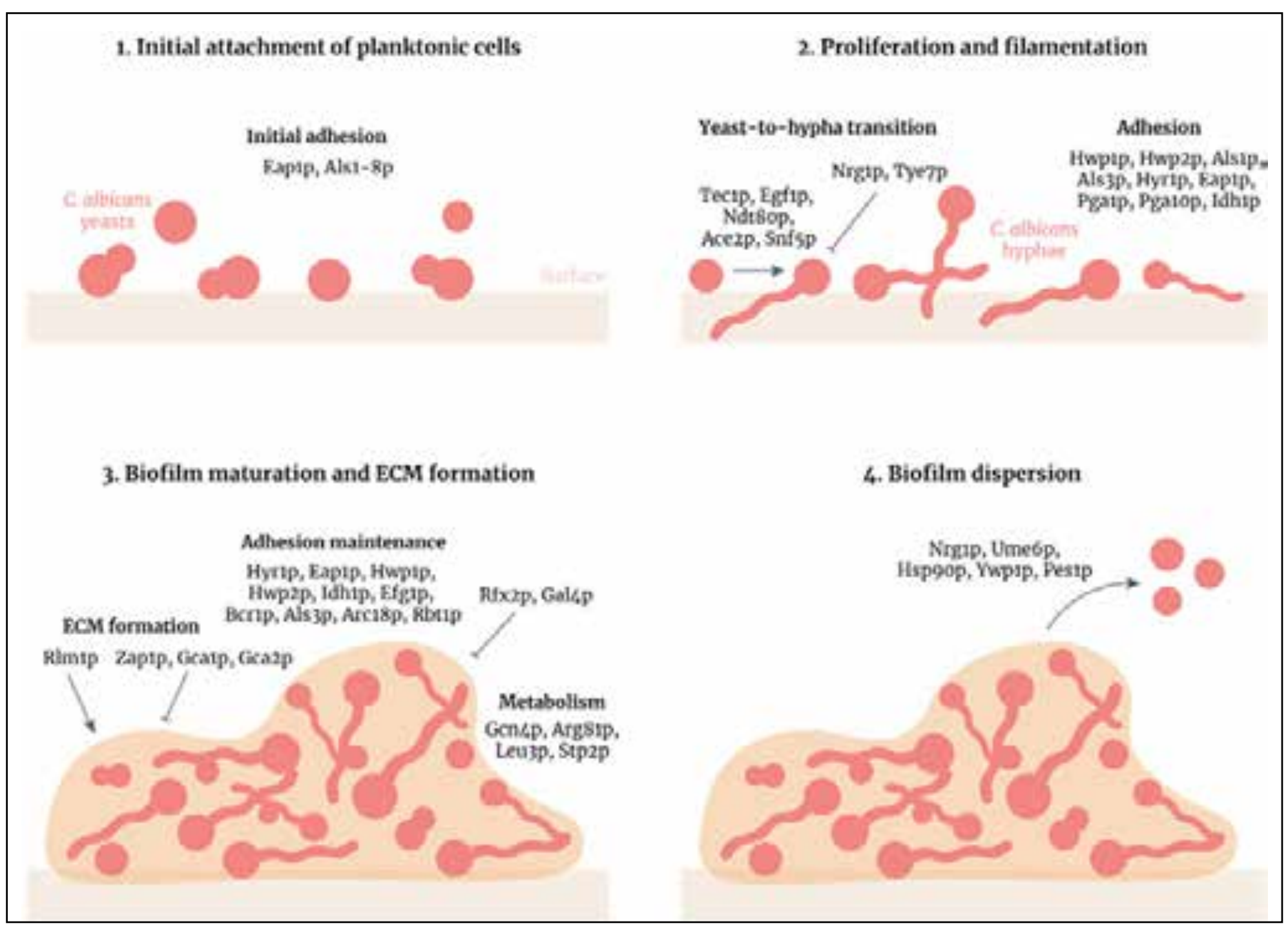

Figure 1: Stages of Candida albicans biofilm formation and development. Candida albicans biofilm formation is a multifactorial process that consists of four main stages. 1) Initial attachment of planktonic cells: C. albicans yeasts attach to a surface (e.g. epithelia, biomaterials or cellular aggregates) through adhesins. 2) Proliferation and filamentation: yeasts transition to hyphae and this process is regulated by many transcription factors 3) Biofilm maturation and extracellular matrix formation: the matrix forms around the C. albicans cells, positively regulated by the TF Rlm1p, providing structural support and protection against antifungals and the host immune system. Adhesion is maintained and amino acid metabolism is increased in the biofilm. 4) Biofilm dispersion: yeast cells disperse from the biofilm to colonise other parts of the body. These cells differ from initial planktonic cells as they are more virulent and more likely to form biofilms. Reprinted from open access reference (23)

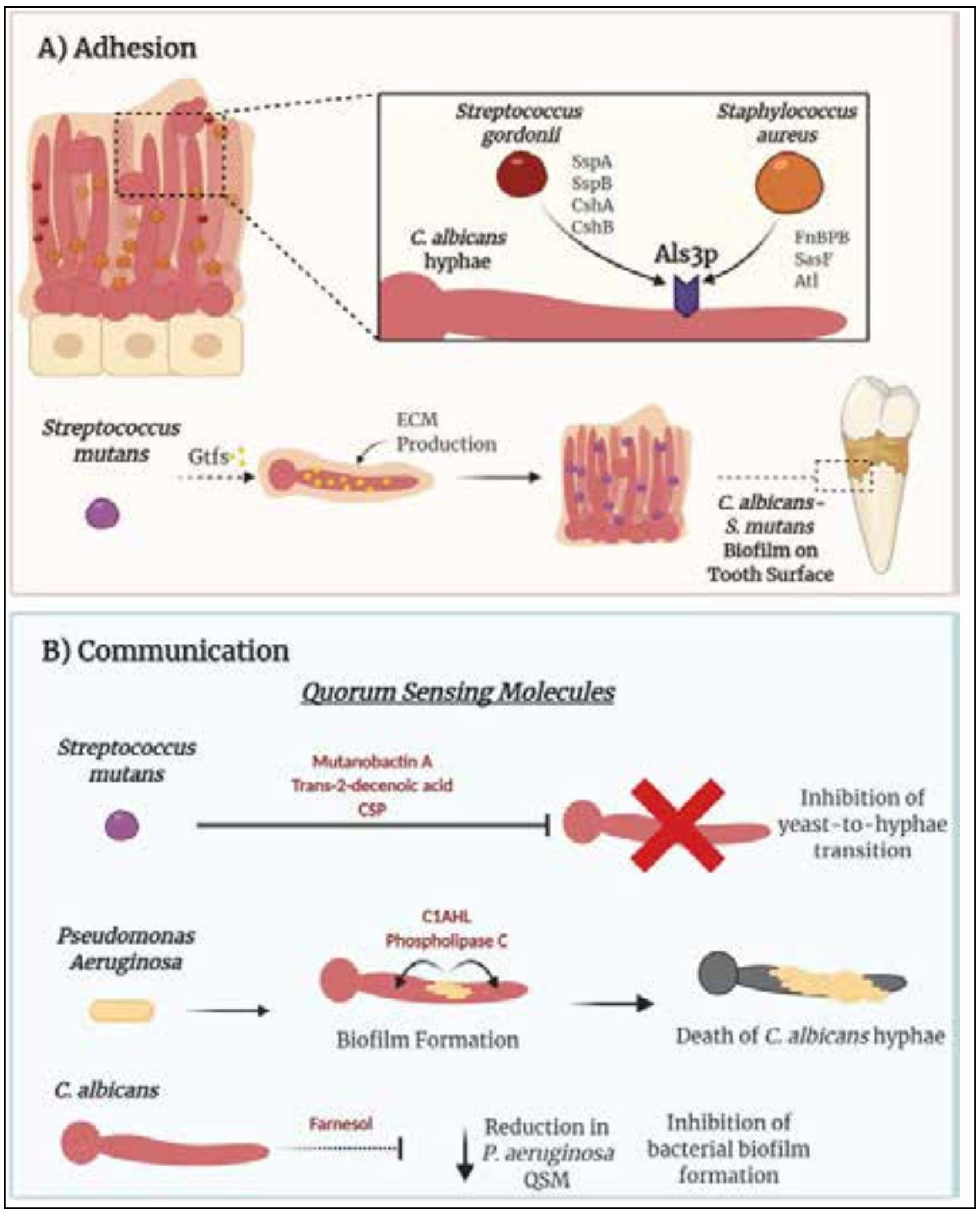

Figure 2: C. albicans interactions within a multispecies biofilm. Complex physical and chemical interactions govern the development of polymicrobial biofilms. A) Several factors influence C. albicans-bacterial adhesion. Staphylococcus aureus and Streptococcus gordonii can utilise C. albicans adhesins to directly bind to hyphae. In contrast, glycosyltransferases (Gtfs) secreted by Streptococcus mutans within the oral cavity can bind to C. albicans mannans, increasing the production of glucans and ECM production. Consequently, the glucan increases the ability of the bacterium to bind to C. albicans and forms a C. albicans-S. mutans biofilm on the tooth surface (dental plaque). B) Signalling molecules produced by C. albicans and bacterial species enable interkingdom communication within multispecies biofilms. For example, S. mutans and Pseudomonas aeruginosa can secrete quorum sensing molecules that influence the behaviour of C. albicans within the biofilm. Likewise, the C. albicans quorum sensing molecule farnesol, can influence the behaviour of interacting bacteria. Reprinted from open access reference (23)

A major factor of the virulence of Candida is its ability to form biofilms, attaching to biotic and abiotic substrates, and forming on synthetic polymers as prosthetic plastics, which are hard to eradicate and are resistant to conventional antifungal treatments [9,23]. Candida Albicans produces larger and more complex biofilm than other Candida species [9], hence it is recommended to remove the device affected, and the biofilm formation passes through 4 stages; i) adsorption and adhesion of C. albicans yeast cells to a substrate, ii) formation of microcolonies and production of extracellular matrix, iii) maturation and iv) dispersal of cells from the mature biofilm, (Fig. 1) [23]. Once formed, the biofilm is highly tolerant to antifungal therapy and can serve as a reservoir for recurrent infection.

It is a common occurrence to have a concomitant bacterial infection among cases of fPJI, ranging between 16%-66%, most commonly Staphylococcus species followed by streptococcus spp. [4,7,21,24]. This wide range of bacterial co-infection could be because the reported cases in literature included primary arthroplasty, re-explored knee joints, revision, and re-revision arthroplasty cases.

One other factor which may explain the high concomitant bacterial infection is the interactions of C. albicans with other microorganisms which can occur via co-aggregation and co-adhesion. C. albicans adhesins facilitate interaction with bacterial species such as Streptococcus gordonii and Staphylococcus aureus, (Fig. 2) [23].

There are several risk factors reported in literature. Fungal PJI occurs most commonly in immune compromised patients, those with previous surgeries and revision cases of joint replacement. Riaz et al. [4,22] reported that antimicrobial therapy within three months before the diagnosis of PJI and the presence of wound drainage lasting longer than five days prior to the diagnosis of PJI are independent risk factors and significantly associated with increased odds of fPJI when compared with bacterial PJI. Other risk factors of fPJI include diabetes, prolonged use of antibiotics, previous PJI and immunosuppression (chemotherapy, cancer patients, HIV, those on corticosteroids, and organ transplant patients), those on indwelling catheter, parenteral nutrition and the illicit IV drug users [4,7,19,25,26-28].

To diagnose fPJI the surgeon should have a high suspension index, especially in high-risk patients. It is not routine to do all diagnostic tests, except in the most uncertain cases. We recommend following the WAIOT 10 golden rules of sampling for diagnosis of PJI, (Fig. 3) [29] and using the WAIOT definition of high and low grade PJI, Table 1 [30].

If fPJI is suspected, as it should be in elderly, revision, or re-revision, and those at risk, a plain x ray is ordered along with leukocyte count, blood culture and serum inflammatory markers (ESR, CRP and D-dimer). The leukocyte count is often normal [5,31,32]. The ESR, CRP and D-dimer may be normal or slightly elevated [4,22,33,34]. Reports are inconsistent, with CRP values between 4 and 31 mg/dl [5,31,32] and ESR values of normal or at the low range, below 60mm/h [5,9,31].

A diagnostic arthrocentesis is performed, unless there is a sinus tract or exposed metal, and surgical debridement is a must [7,13,35]. Aspirate is analysed for low sugar, high protein, and cell count (more than 3000), although they may be of limited value [19]. The aspirate is sent for both bacterial and fungal cultures, the latter will take up to 4 weeks or longer [19]. Intraoperative samples are taken in accordance with WAIOT 10 rules and sent for cultures and histopathology [29]. Fungi are notoriously difficult to isolate

Figure 3: Microbiology best practice for the diagnosis of peri-prosthetic joint infections and implant-related infections in ortho-trauma. The 10 WAIOT golden rules. Reprinted with permission of Publisher. Open access reference [29]

[19], and although Candida is readily recovered using blood culture bottles (BCB) [36], but Sabouraud dextrose brain heart infusion (BHI) or plain BHI are universal media for most fungi, and other special media are required for other types of fungi [37,38].

More sophisticated serology and molecular tests are not readily available, and their clinical use is still under investigation and include organism-specific antigens, serum beta-glucan, enzyme immunoassays, DNA based tests and mass spectrometry [20,39]. In some culture -negative cases, uncultivable organisms should be considered, and other identification techniques are performed, such as polymerase chain reaction (PCR) and next generation sequencing (NGS) [4,40]. Radiological assessment and diagnoses are beyond the scope of this review, but in fPJI all what may be needed is a plain x-ray. Although radionucleotide scans, MRI and CT are used in other fungal infections, their use in diagnosing and managing PJI is questionable [7,41-43].

DISCUSSION

The literature lacks both evidence and clear algorithm regarding the best treatment approach in treating fPJI, but there has been preference toward certain surgical approaches and recommendations regarding both medical and surgical managements [4,5,7,19,44].

Regarding medical treatment, the Infectious Disease Society of America (IDSA) guidelines for the duration of treatment with antifungal agents in the treatment of joint arthritis are 6 to 12 months [12]. For Candida PJI, the European Society for

	No Infection	Contamination	BIM	LG-PJI	HG-PJI
Clinical presentation	One or more condition(s), other than infection, can cause the symptoms or the reason for reoperation (e.g., wear debris, metallosis, recurrent dislocation or joint instability, fracture, malposition, neuropathic pain)		One or more of the followings: otherwise "unexplained" pain, swelling, stiffness		Two or more of the followings: pain, swelling, redness, warmth, *functio laesa*
# of Positive Rule IN minus # of Negative Rule OUT tests	<0	<0	<0	≥0	≥1
Post-operatively confirmed if	Negative cultural examination	One pre- or intra-operative positive culture, with negative histology	Positive cultural examination (preferably with antibiofilm techniques) and/or positive histology		

Abbreviations: WAIOT: World Association against Infection in Orthopedics and Trauma; BIM: Biofilm-related Implant malfunction; LG-PJI: Low-Grade Peri-Prosthetic Joint Infection; HG-PJI: High-Grade Peri-Prosthetic Joint Infection.

Table 1: WAIOT proposed definition of peri-prosthetic joint infection (PJI)

Clinical Microbiology and Infectious Disease recommends implant removal with at least 14 days of parenteral antifungals followed by a subsequent minimum of 4 to 6 weeks of oral agents [4,45,46]. In the case of two-stage exchange, the International Consensus Meeting (ICM) recommends a minimum of 6 weeks antifungal treatment after prosthesis removal [4,47]. A meta-analysis by Ueng et al. [8] identified an improved eradication of infection with prolonged systemic therapy from 3-6 months.

There is no agreement on the optimal choice of antifungal medication or whether to use monotherapy or combined therapy and the choice should be driven by resistance patterns and patient factors as well as the chronicity of the case. Most reports favor fluconazole, variconazole and amphotericin B [4,5,7]. The liposomal compounds of amphotericin B have a better record in reducing nephrotoxicity [7,48,49]. There are no existing guidelines for the use of prophylactic anti-fungal therapy in high-risk, immunocompromised patients going for total joint replacement [7].

There has not been adequate studies of the elution characteristics of antifungal agents from bone cement (PMMA) or calcium sulphates, although the commonly used amphotericin B was reported to have the longest elution properties of up to 100 days, but other agents including fluconazole and variconazole have been used also [7,50]. A few papers have reported both In-vitro and In-vivo result to know more of the elution properties of antifungal agents as well as finding the best vehicle to assure a higher concentrations and longer elution. Butcher MC et al. [51] has reported on antifungal-loaded triple agents (fluconazole (FLZ), amphotericin B (AMB), and caspofungin (CSP), calcium sulfate beads, producing a sustained antimicrobial effect that inhibits and kills clinically relevant fungal species in vitro as planktonic and biofilm cells. Romera D et al. [52] have reported a Novel hybrid organo-inorganic sol-gel coating of fluconazole or anidulafungin, with the highest concentration to prevent and locally treat yeast PJI. They have showed an excellent anti-biofilm behavior. Coatings loaded with fluconazole proved to be effective against both Candida species. The use of resorbable beads have been reported by Yung-Heng Hsu et al. [53]. They reported a high level of fluconazole (beyond the minimum therapeutic concentration [MTC]) release for more than 49 days, using biodegradable compression-molded PLGA (Poly(d,l-lactide-co-glycolide) / fluconazole beads.

Following surgical debridement, reports have had different approaches in dealing with fungal PJI. The numbers reported are small to draw firm conclusions, although recent meta-analysis and systematic reviews have shed more light into the best surgical approach in dealing with fPJI. The options at hand are DAIR (Debridement, Antibiotics, Implant Retention), one stage revision arthroplasty (Single-SRA), two stage revision arthroplasty (Two-SRA), three stage revision arthroplasty (Three-SRA), resection arthroplasty, arthrodesis, and amputation [4,5,7,19,21,24,54].

It has to be noted that amputation, arthrodesis, and resection arthroplasty (RA) may highly diminish the quality of life of the patients and the reported success rate of RA and arthrodesis from small series and heterogeneous reports is 80% and 67% respectively [7,27], and that of amputation is 66% only [55]. Therefore, they should be sought of as a salvage procedure in the most resistance cases or those with repeated uncontrollable infection despite multiple procedures and long anti-fungal treatment. The reported surgical treatment methods come from small case series, case reports and systematic reviews and are heterogeneous [4,5,7,12,19,26,27,44,56].

Debridement, antibiotic, and implant retention (DAIR) have been used in small number of cases and mainly in cases reported within 4 weeks of the primary procedure and often resulting in persistent infection and 20-30% success rate only [4,5,24,31]. For bacterial PJI, the consensus is that chronic infections should never be treated with DAIR, and the same has been suggested for fPJI, unless revision surgery is contraindicated or refused by the patient after adequate information [13,24,63].

In a recent systematic review, Sambri et al. [4] and Koutserimpas et al. [7] reported a predominance favoring of Two-SRA, (64.2%) and (54%) respectively. Other authors also reported a preference of Two-SRA among surgeons [9,11,19,24,26,27,55]. A success rate of over 92% has been reported for Two-SRA [7,57,58], although there is wide variability of success rate. Anagnostakos et al. [58]

reported a 100% success in a small series of 7 patients. Haleem et al reported infection eradication up to above 90% [4, 57]. Kuiper et al [24] reported an 84.8% success rate, and Phelan et al [59] reported 80%. On the other hand, Azzam et al. [9] reported a 47.4% success rate only. It is notable that the success rate diminishes in the case of bacterial co-infection [7].

The optimal time interval for reimplantation is unknown. A minimum of six weeks is usually recommended [19,24], although this is extended to 3-6 months in revision and re-revision cases [7]. In all cases reimplantation is performed when the clinical picture and blood markers have come to normal [24]. There is no conclusive evidence to support the use of an antimicrobial holiday period prior to reimplantation in case of fungal PJI treated with staged revision [21].

The Single-SRA has been used and reported with discordant results. A success rate of 90% has been reported by Klatte et al (60) in a small series of 10 patients. On the other hand, Ji et al [61] reported a recurrence rate of 36%. Others have reported a 75% success rate [7]. A Single-SRA might be considered in patients with unfit medical situation or those who may not tolerate multiple procedures, along with prolonged anti-fungal therapy.

The gold standard of bacterial PJI has been the Two-SRA, although Gregor Dersch and Heinz Winkler [62] have reported favorable and encouraging results of Single-SRA by using Antibiotic-Impregnated Cancellous Allograft Bone, on 70 cases. Whether their technique could be adopted for fPJI is for future research to decide.

Recently, a three-SRA for fungal PJI was reported and claimed 88.8% success [54]. This technique is in accordance with the recommendations of PRO-IMPLANT Foundation for difficult to treat (DDT) microorganisms [64]. The principles of this algorithm include, but are not limited to, the following key points:

1. no drug holidays prior to reimplantation of the prosthesis;
2. no joint aspiration before reimplantation;
3. biofilm-active therapy only after reimplantation;
4. antimicrobial therapy for 12 weeks from the date of last positive microbiological evidence (six months for fungal agents);
5. the three-stage exchange procedure must not alter the predetermined interval of six weeks from ex-plantation to reimplantation.

First stage; debridement, removal of implant (sonication & culture). A custom-made cement spacer loaded with 0.4 g liposomal amphotericin B and voriconazole 0.4 g combined with 1 g gentamicin and 2 vancomycin per 40 g cement powder is used. If fungi not diagnosed preoperatively 1 g Gentamycine and 2 g Vancomycine spacer is used only.

Second stage; 3 weeks revision, debridement, and exchange of spacer. The same custom-made cement spacer with amphotericin B and voriconazole is used again to ensure continuously high local antimycotic therapy. The residual AB therapy will be adapted according to sonication.

Third stage; 3 weeks reimplantation. Again, debridement and final implantation of revision implant with custom made cement including amphotericin B 0.2 g and Voriconazol 0.2 g combined with 0.5 g Gentamicin and 2 g vancomycin is performed. This is followed by six months systemic anti-fungal treatment which is switched to oral after uneventful postoperative period and wound healing. While Two-SRA appears as the most adopted surgical approach, there are no comparative studies, showing its superiority over Single-SRA, while the overall results of a 3-stage revision surgery do not seem to provide a substantial benefit, compared to 2-stage. In this regard, it should be noted that staged procedures are inevitably associated with additional operative risks, prolonged duration of the treatment and higher costs and an increase of the number of several subsequent procedures should be well balanced in each patient, weighing the potential benefits and risks.

RECOMMENDATIONS AND CONCLUSION

According to the presented data and review of literature, we believe that we can recommend the following generally agreed approach in treating fungal PJI, even if the specific treatment for each patient must be decided by the surgical team after open discussion with the patient and based on the general and local conditions, the clinical history and the expectations of the patient:

1. **No DAIR**, unless for selected cases, in which revision surgery is contraindicated or not accepted by the patient after adequate information.
2. **One stage revision should be performed** by an experienced surgeon, at ease with the Single-SRA procedure and having a high turnover of cases. With this in mind, it may be considered in ASA type one patients, and on the opposite, in a patient with compromised medical condition or status that would put him at high risk in case of multiple procedures.
3. **Two stage revision should be considered as the gold standard for fungal PJI**
4. Consider **three-SRA in difficult cases** as re-revisions and patients with multiple risk factors.
5. **Reimplantation is not performed until there are no clinical signs of infectious symptoms**, normalization of infection parameters and after a minimum of 6 weeks from index surgery.
6. **No antimicrobial holiday periods.**
7. **Six months of systemic anti-fungal treatment.** The antifungal treatment should better see a strict cooperation between the infectious disease specialist and/or clinical microbiologist and the surgical team.
8. **Cement spacers should have liposomal amphotericin B, as well as vancomycin/gentamycin**, as there is high percentage of bacterial co-infection.
9. **Spacer with a mixture of fluconazole (FLZ), liposomal amphotericin B (AMB), and caspofungin (CSP)** gave promising results in fPJI and may be considered in the more chronic cases.
10. **There is a need for establishing an algorithm of fungal PJI**, preferably on the basis of comparative prospective studies or a sound meta-analysis and systematic review of available studies.

We believe that fPJI management lacks proper evidence and high volume, multi-center studies to draw sound conclusions regarding anti-fungal therapy agents, duration, combination treatment and success, as well as the best surgical options. In addition, more studies on the elution of antifungal agents, the minimum time interval between the two stages as well as establishing potent antibiofilm, antimicrobial agents and the possibility of using antifungal medications impregnation in bone graft in Single-SRA. These questions cannot be answered without the collaboration between multiple centers worldwide. ■

Bibliography

1. **Kobayashi G S. (1990). Fungi. In: Davis B D, Dulbecco R, Eisen H N, Ginsberg H S, eds.** Microbiology. Philadelphia: Lippincott, 737-65.

2. **Marta L Cuellar, Luis H Silveira, Luis R Espinoza. (1992). Fungal Arthritis.** Annals of Rheumatic Diseases, 51: 690-697.

3. **Ehrlich G E. (1978). Fungal arthritis [editorial].** JAMA, 240:563.

4. **Sambri, A.; Zunarelli, R.; Fiore, M.; Bortoli, M.; Paolucci, A.; Filippini, M.; Zamparini, E.; Tedeschi, S.; Viale, P.; De Paolis, M. (2023). Epidemiology of Fungal Periprosthetic Joint Infection: A Systematic Review of the Literature.** Microorganisms, 11, 84 https://doi.org/10.3390/microorganisms11010084.

5. **Saconi ES, Carvalho VC, Oliveira PR, Lima AL. (2020). Prosthetic joint infection due to Candida species: case series and review of literature.** Medicine, 99:15(e19735)

6. **Bariteau JT, Waryasz GR, McDonnell M, Fischer SA, Hayda RA, Born CT. (2014). Fungal osteomyelitis and septic arthritis.** J Am Acad Orthop Surg. Jun;22(6):390-401. doi: 10.5435/JAAOS-22-06-390. PMID: 24860135.

7. **Koutserimpas, C.; Naoum, S.; Alpantaki, K.; Raptis, K.; Dretakis, K.; Vrioni, G.; Samonis, G. (2022). Fungal Prosthetic Joint Infection in Revised Knee Arthroplasty: An Orthopaedic Surgeon's Nightmare.** Diagnostics, 12, 1606. https://doi.org/ 10.3390/diagnostics12071606.

8. **Ueng AWN, Lee C, Hu C, et al. (2013). What is the success of treatment of hip and knee candidal periprosthetic joint infection.** Clin Orthop Relat Res, 471:3002–9.

9. **Azzam K, Parvizi J, Jungkind D, et al. (2009). Microbiological, clinical, and surgical features of fungal prosthetic joint infections: a multi-institutional experience.** J Bone Jt Surg Am, 91(Suppl 6):142–9.

10. **Wang Q-J, Shen H, Zhang X-L, et al. (2015). Staged reimplantation for the treatment of fungal peri-prosthetic joint infection following primary total knee arthroplasty.** Orthop Traumatol Surg Res, 101:151–6.

11. **Parvizi J, Gehrke T, Chen AF. (2013). Proceedings of the international consensus meeting on periprosthetic joint infection.** Bone Joint J,95-B:1450–2.

12. **Pappas PG, Kauffman CA, Andes DR, Clancy CJ, Marr KA, Ostrosky-Zeichner L, Reboli AC, Schuster MG, Vazquez JA, Walsh TJ, Zaoutis TE, Sobel JD. (2016). Clinical Practice Guideline for the Management of Candidiasis: 2016 Update by the Infectious Diseases Society of America.** Clin Infect Dis. Feb 15;62(4):e1-50. doi: 10.1093/cid/civ933. Epub 2015 Dec 16. PMID: 26679628; PMCID: PMC4725385.

13. **Osmon DR, Berbari EF, Berendt AR, et al. (2013). Diagnosis and management of prosthetic joint infection: clinical practice guidelines by the Infectious Diseases Society of America.** Clin Infect Dis, 56: e1–25.

14. **Gebauer M, Frommelt L, Acham P, et al. (2014). Management of fungal or atypical periprosthetic joint infections. J** Orthop Res,32: s147–51.

15. **Parvizi, J.; Tan, T.L.; Goswami, K.; Higuera, C.; Della Valle, C.; Chen, A.F.; Shohat, N. (2018). The 2018 Definition of Periprosthetic Hip and Knee Infection: An Evidence-Ba. sed and Validated Criteria.** J. Arthroplast., 33, 1309–1314.e2. [CrossRef] [PubMed].

16. **Izakovicova, P.; Borens, O.; Trampuz, A. (2019). Periprosthetic joint infection: Current concepts and outlook.** EFORT Open Rev., 4, 482–494. [CrossRef]

17. **Ullmann, A.J.; Aguado, J.M.; Arikan-Akdagli, S.; Denning, D.W.; Groll, A.H.; Lagrou, K.; Lass-Flörl, C.; Lewis, R.E.; Munoz, P.; Verweij, P.E.; et al. (2018). Diagnosis and management of Aspergillus diseases: Executive summary of the 2017 ESCMID-ECMM-ERS guideline.** Clin. Microbiol. Infect., 24 (Suppl. S1), e1–e38.

18. **Parvizi, J.; Gehrke, T.; Chen, A.F. (2013). Proceedings of the International Consensus on Periprosthetic Joint Infection.** Bone Jt. J., 95, 1450–1452. [CrossRef]

19. **E. Chisari, F. Lin, J. Fei et al. (2022). Fungal periprosthetic joint infection: Rare but challenging problem.** Chinese Journal of Traumatology 25, 63-66.

20. **Eric M. Ruderman, John P. Flaherty. (2016). Fungal infections of bone and joints.** In Muskuloskeletal Key search engine, chapter 112,2015.

21. **Theil C, Schmidt-Braekling T, Gosheger G, Idelevich EA, Moellenbeck B, Dieckmann R. (2019). Fungal prosthetic joint infection in total hip or knee arthroplasty: a retrospective single-centre study of 26 cases.** Bone Joint J. May;101-B(5):589-595. doi: 10.1302/0301-620X.101B5.BJJ-2018-1227.R2. PMID: 31038988.

22. **Talha Riaz, Aaron J. Tande, Lisa L. Steed, Harry A. Demos, Cassandra D. Salgado, Douglas R. Osmon, Camelia E. Marculescu. (2020). Risk Factors for Fungal Prosthetic Joint Infection.** J. Bone Joint Infect. 5(2): 76-81. doi: 10.7150/jbji.40402.

23. **Ponde NO, Lortal L, Ramage G, Naglik JR, Richardson JP. (20210. Candida albicansbiofilms and polymicrobial interactions.** Crit Rev Microbiol. 2021 Feb;47(1):91-111. doi: 10.1080/1040841X.2020.1843400. Epub, Jan 22. PMID: 33482069; PMCID: PMC7903066.

24. **Kuiper JW, van den Bekerom MP, van der Stappen J, Nolte PA, Colen S. (2013). 2-stage revision recommended for treatment of fungal hip and knee prostheticjoint infections.** Acta Orthop. Dec;84(6):517-23. doi: 10.3109/17453674.2013.859422. Epub 2013 Oct 31. PMID: 24171675; PMCID: PMC3851663.

25. **Maria N Gamaletsou, Thomas J Walsh, Nikolaos V Sipsas. (2014). Epidemiology of Fungal Osteomyelitis.** Current Fungal Infection Reports, Dec 8 (4): 262-270.

26. **Koutserimpas, C.; Chamakioti, I.; Zervakis, S.; Raptis, K.; Alpantaki, K.; Kofteridis, D.P.; Vrioni, G.; Samonis, G. (2021). Non-Candida Fungal Prosthetic Joint Infections.** Diagnostics, 11, 1410. [CrossRef]

27. **Koutserimpas, C.; Zervakis, S.G.; Maraki, S.; Alpantaki, K.; Ioannidis, A.; Kofteridis, D.P.; Samonis, G. (2019). Non-albicans Candida prosthetic joint infections: A systematic review of treatment.** World J. Clin. Cases, 7, 1430–1443. [CrossRef] [PubMed]

28. **Koutserimpas, C.; Samonis, G.; Velivassakis, E.; Iliopoulou-Kosmadaki, S.; Kontakis, G.; Kofteridis, D.P. (2018). Candida glabrata prosthetic joint infection, successfully treated with anidulafungin: A case report and review of the literature.** Mycoses, 61,266–269[CrossRef] [PubMed].

29. **Drago L, Clerici P, Morelli I, Ashok J, Benzakour T, Bozhkova S, Alizadeh C, Del Sel H, Sharma HK, Peel T, Mattina R, Romanò CL. (2019). The World Association against Infection in Orthopaedics and Trauma (WAIOT) procedures for Microbiological Sampling and Processing for Periprosthetic Joint Infections (PJIs) and other Implant-Related Infections.** J Clin Med., Jun 28;8(7):933. doi: 10.3390/jcm8070933. PMID: 31261744; PMCID: PMC6678965.

30. **Romanò CL, Khawashki HA, Benzakour T, Bozhkova S, Del Sel H, Hafez M, Johari A, Lob G, Sharma HK, Tsuchiya H, Drago L; (2019). World Association against Infection in Orthopedics and Trauma (W.A.I.O.T.) Study Group on Bone and Joint Infection Definitions. The W.A.I.O.T. Definition of High-Grade and Low-Grade Peri-Prosthetic Joint Infection.** J Clin Med., May 10;8(5):650. doi: 10.3390/jcm8050650. PMID: 31083439; PMCID: PMC6571975.

31. **Hwang BH, Yoon JY, Nam CH, et al. (2012). Fungal peri-prosthetic joint infection after primary total knee replacement.** J Bone Joint Surg Br, 94:656–9.

32. Klatte TO, Junghans K, Al-Khateeb H, et al. (2013). Single-stage revision for peri-prosthetic shoulder infection: outcomes and results. Bone Jt J, 95B:391–5.

33. Bracken, C.D.; Berbari, E.F.; Hanssen, A.D.; Mabry, T.M.; Osmon, D.R.; Sierra, R.J. (2014). Systemic inflammatory markers and aspiration cell count may not differentiate bacterial from fungal prosthetic infections. Clin. Orthop. Relat. Res., 472, 3291–3294. [CrossRef]

34. Pérez-Prieto, D.; Portillo, M.E.; Puig-Verdié, L.; Alier, A.; Martínez, S.; Sorlí, L.; Horcajada, J.P.; Monllau, J.C. (2017). C-reactive protein may misdiagnose prosthetic joint infections, particularly chronic and low-grade infections. Int. Orthop., 41, 1315–1319. [CrossRef]

35. Beam, E.; Osmon, D. (2018). Prosthetic Joint Infection Update. Infect. Dis. Clin. N. Am., 32, 843–859. [CrossRef]

36. Tai DBG, Wengenack NL, Patel R, Berbari EF, Abdel MP, Tande AJ. (2022). Fungal and mycobacterial cultures should not be routinely obtained for diagnostic work-up of patients with suspected periprosthetic joint infections. Bone Joint J., 104-B (1):53-58. doi: 10.1302/0301-620X.104B1.BJJ-2021-0876.R1

37. Bosshard PP. (2011). Incubation of fungal cultures: how long is long enough? Mycoses., 54:539e545. https://doi.org/10.1111/j.1439-0507.2010.01977.x.

38. Williamson MA, Snyder LM, Wallach JB. (2011). Wallach's Interpretation of Diagnostic Tests: Pathways to Arriving at a Clinical Diagnosis. Philadelphia, PA: Wolters

39. Benoit Pilmis, et.al. (2017). In Infectious Diseases, 439-470 (4th edition), Elsevier Limited.

40. Nace, J.; Siddiqi, A.; Talmo, C.T.; Chen, A.F. (2019). Diagnosis and Management of Fungal Periprosthetic Joint Infections. J. Am. Acad. Orthop. Surg., 27, e804–e818. [CrossRef]

41. Carol A. Kemper, Stanley C. Deresinski. (2009). In clinical Mycology, 525-546 (2nd edition), Churchill Livingstone/Elsevier

42. Elizabeth G. Demicco, et.al. (2018). In Diagnostic Pathology of Infectious Disease, 404-428 (2nd edition), Elsevier

43. Prasanna G. Vibhute, et.al. (2009). In Clinical Mycology 109-159 (2nd edition), Churchill Livingstone/Elsevier

44. Cobo F, Rodríguez-Granger J, Sampedro A, Aliaga-Martínez L, Navarro-Marí JM. Candida Prosthetic Joint Infection. (2017). A Review of Treatment Methods. J Bone Jt Infect. Feb 5;2(2):114-121. doi: 10.7150/jbji.17699. PMID: 28540147; PMCID: PMC5441142.

45. Izakovicova, P.; Borens, O.; Trampuz, A. (2019). Periprosthetic joint infection: Current concepts and outlook. EFORT Open Rev., 4,482–494. [CrossRef]

46. Ullmann, A.J.; Aguado, J.M.; Arikan-Akdagli, S.; Denning, D.W.; Groll, A.H.; Lagrou, K.; Lass-Flörl, C.; Lewis, R.E.; Munoz, P.; Verweij, P.E.; et al. (2018). Diagnosis and management of Aspergillus diseases: Executive summary of the 2017 ESCMID-ECMM-ERS guideline. Clin. Microbiol. Infect., 24 (Suppl. S1), e1–e38.

47. Parvizi, J.; Gehrke, T.; Chen, A.F. (2013). Proceedings of the International Consensus on Periprosthetic Joint Infection. Bone Jt. J., 95, 1450–1452. [CrossRef]

48. Hamill, R.J. Amphotericin B formulations: (2013). A comparative review of efficacy and toxicity. Drugs, 73, 919–934. [CrossRef] [PubMed]

49. Nett, J.E.; Andes, D.R. (2016). Antifungal Agents: Spectrum of Activity, Pharmacology, and Clinical Indications. Infect. Dis. Clin. N. Am., 30, 51–83. [CrossRef] [PubMed]

50. Henry MW, Miller AO, Walsh TJ, Brause BD. (2017). Fungal Musculoskeletal Infections. Infect Dis Clin North Am. Jun;31(2):353-368. doi10.1016/j.idc.2017.01.006. PMID: 28483045.

51. Mark C. Butcher, Jason L. Brown, Donald Hansom, Rebecca Wilson-van Os,Craig Delury,Phillip A. Laycock,Gordon Ramagea. (2021). Assessing the Bioactive Profile of Antifungal-Loaded Calcium Sulfate against Fungal Biofilms. Antimicrob Agents Chemother., 05 18; 65(6)

52. David Romera , Beatriz Toirac, John-Jairo Aguilera-Correa, Amaya García-Casas, Aránzazu Mediero, Antonia Jiménez-Morales and Jaime Esteban.(2020). A Biodegradable Antifungal-Loaded Sol–Gel Coating for the Prevention and Local Treatment of Yeast Prosthetic-Joint Infections. Materials (Basel). Jul 15; 13(14).

53. Yung-Heng Hsu, Huang-Yu Chen, Jin-Chung Chen, Yi-Hsun Yu. (2019). Resorbable Beads Provide Extended Release of Antifungal Medication: In Vitro and In Vivo Analyses. Pharmaceutics, October, 11(11):550

54. Baecker H, Frieler S, Geßmann J, Pauly S, Schildhauer TA, Hanusrichter Y. (2021). Three-stage revision arthroplasty for the treatment of fungal periprosthetic joint infection: outcome analysis of a novel treatment algorithm: a prospective study. Bone Jt Open., Aug;2(8):671-678. doi: 10.1302/2633-1462.28.BJO-2021-0002.R2. PMID: 34406077; PMCID: PMC8384437.

55. Enz, A.; Mueller, S.C.; Warnke, P.; Ellenrieder, M.; Mittelmeier, W.; Klinder, A. (2021). Periprosthetic Fungal Infections in Severe Endoprosthetic Infections of the Hip and Knee Joint-A Retrospective Analysis of a Certified Arthroplasty Centre of Excellence. J. Fungi, 7, 404. [CrossRef] [PubMed]

56. Cobo F, Rodríguez-Granger J, López EM, Jiménez G, Sampedro A, Aliaga-Martínez L, Navarro-Marí JM. (2017). Candida-induced prosthetic joint infection. A literature review including 72 cases and a case report. Infect Dis (Lond). Feb;49(2):81-94. doi: 10.1080/23744235.2016.1219456. Epub 2016 Sep 1. PMID: 27586845.

57. Haleem, A.A.; Berry, D.J.; Hanssen, A.D. (2004). Mid-term to long-term followup of two-stage reimplantation for infected total knee arthroplasty. Clin. Orthop. Relat. Res., 35–39. [CrossRef]

58. Anagnostakos, K.; Kelm, J.; Schmitt, E.; Jung, J. (2012). Fungal periprosthetic hip and knee joint infections clinical experience with a 2-stage treatment protocol. J. Arthroplast., 27, 293–298. [CrossRef] [PubMed]

59. Phelan, D.M.; Osmon, D.R.; Keating, M.R.; Hanssen, A.D. (2002). Delayed reimplantation arthroplasty for candidal prosthetic joint infection: A report of 4 cases and review of the literature. Clin. Infect. Dis., 34, 930–938. [CrossRef]

60. Klatte, T.O.; Kendoff, D.; Kamath, A.F.; Jonen, V.; Rueger, J.M.; Frommelt, L.; Gebauer, M.; Gehrke, T. (2014). Single-stage revision for fungal peri-prosthetic joint infection: A single-centre experience. Bone Jt. J., 96, 492–496. [CrossRef]

61. Ji, B.; Zhang, X.; Xu, B.; Guo, W.; Mu, W.; Cao, L. (2017). Single-Stage Revision for Chronic Fungal Periprosthetic Joint Infection: An Average of 5 Years of Follow-Up. J. Arthroplast., 32, 2523–2530. [CrossRef]

62. Dersch, G.; Winkler, H. Periprosthetic Joint Infection (PJI)—Results of One-Stage Revision with Antibiotic-Impregnated Cancellous Allograft Bone—A Retrospective Cohort Study. Antibiotics 2022, 11, 310. https://doi.org/10.3390/antibiotics11030310

63. Crockarell JR, Hanssen AD, Osmon DR, Morrey BF. (1998). Treatment of infection with debridement and retention of the components following hip arthroplasty. J Bone Joint Surg (Am);80(9):1306–13. [PubMed] [Google Scholar]

64. Izakovicova P, Borens O, Trampuz A. (2019). Periprosthetic joint infection: current concepts and outlook. EFORT Open Rev.;4(7):482–494

SEPTIC ARTHRITIS OF THE NATIVE HIP BY GRANULICATELLA ADIACENS
A CASE REPORT AND LITERATURE REVIEW

German VIALE, Hernán DEL SEL, Santiago GRANDE, German GARABANO

Dept Orthopaedics and Traumatology, British Hospital of Buenos Aires, Argentina
hdelsel@argentina.com

INTRODUCTION

Septic arthritis of the native hip is a rare condition in the adult population [1]. Its incidence has been reported at approximately 2 to 10 per 100,000 person-years [2]. Granulicatella adiacens is a nutritional variant of streptococcus known to be a commensal of the oral flora [3]. This germ has been involved as a causative pathogen mainly in endocarditis and less frequently in infections of other systems [2-4]. To our knowledge, there are no reports of this microorganism as a cause of septic arthritis of the native hip. Therefore, this paper aims to present a case of septic arthritis of the native hip caused by this fastidious germ.

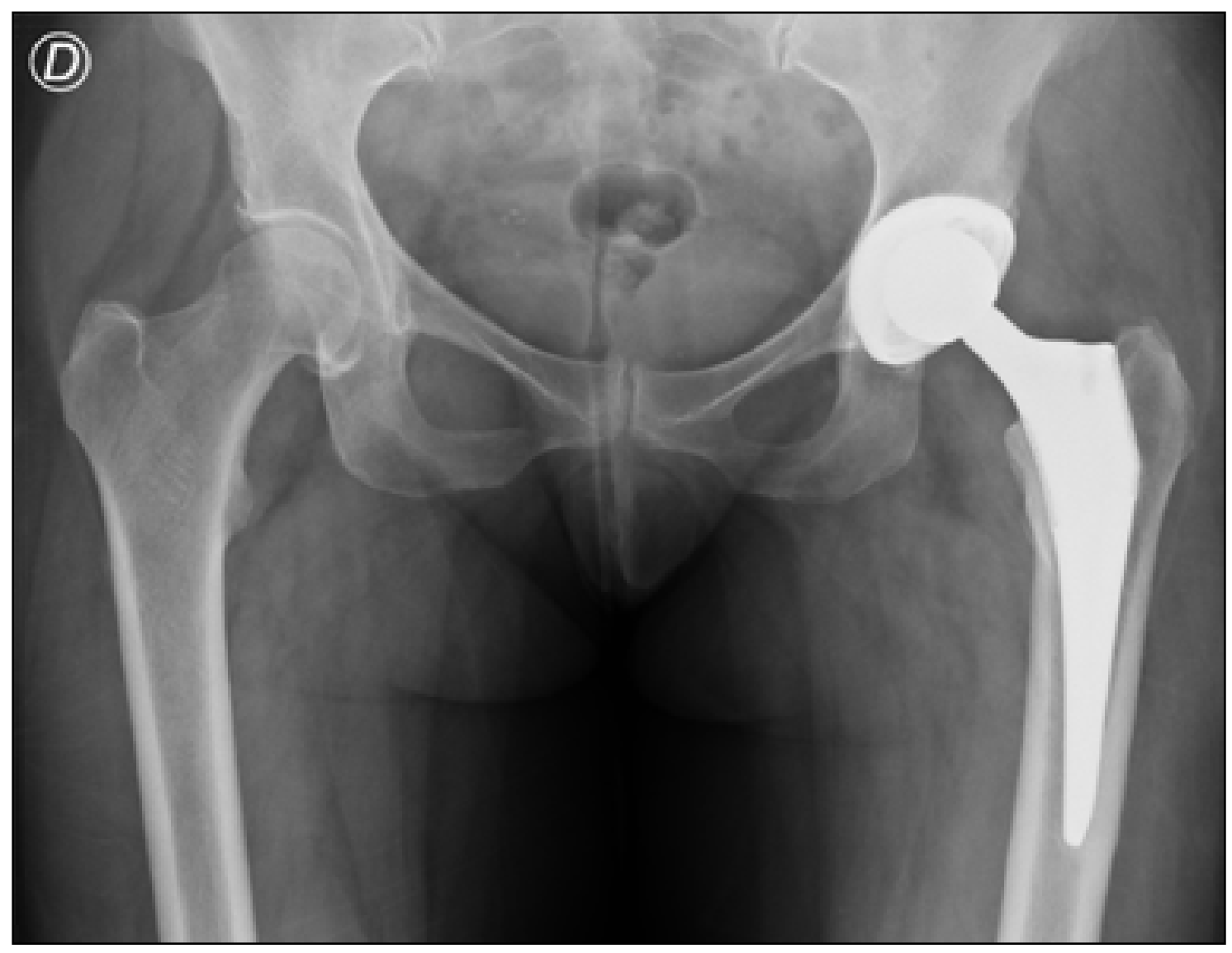

Figure 1: AP radiograph at two months after the onset of symptoms showing a normal joint space in the right hip, and a left THA.

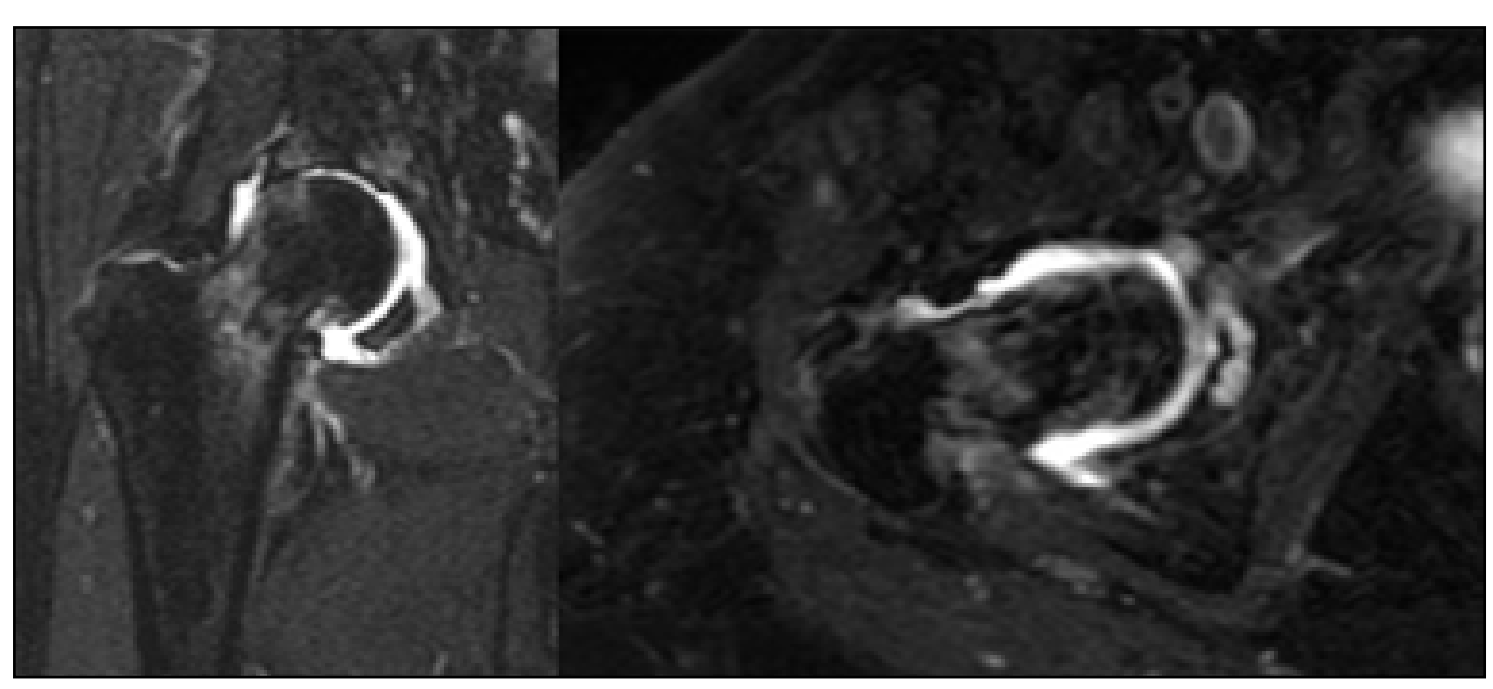

Figure 2: First MRI showing increased synovial fluid.

CASE

A 58-year-old woman consulted at our department with a history of high blood pressure, dyslipidemia and primary uncemented left total hip arthroplasty for osteoarthritis 9 months before, with a satisfactory result and a Harris Hip Score of 92 points. She presented walking without assistance complaining of right hip pain of 2 months duration. She referred dull pain, with an intensity of 5 on the visual analog scale and having received a steroid injection in the painful hip 6 weeks after the onset of symptoms and 15 days before consultation. Physical examination showed moderate pain during motion, with hip flexion 10 to 100°, internal rotation of 15° and external rotation of 20°. There was no fever or erythema in the area. At that time, an X-ray of both hips was performed which showed a normal right hip and left THA (Figure 1).

As a complementary method of diagnosis, we requested an MRI. The following week she returned with an MRI, using an elbow crutch on the left hand due to increased pain (Visual Analog Scale 9) and intolerance to weight bearing. The MRI showed an increase in synovial fluid in the right hip (Figure 2). With suspicion of septic arthritis, we performed an arthrocentesis in the operating room and requested a blood test with infection related makers (normal values: White Blood Cell Counts < 9000 mm3, Erythrocyte sedimentation rate < 16mm/1st hour, C-reactive Protein <0.3mg/dL). Results were compatible with infection: WBC 16500mm3, ESR:26 and CRP: 0.1mg/dL. We decided to perform an arthroscopic lavage and collection of samples for bacteriological culture.

An empirical antibiotic therapy with Vancomycin and Ceftazidime was started. After one week (day 8) of culture in enriched media, Granulicatella adiacens was recovered and, according to the antibiogram, ATB was adapted to Ceftriaxone 1g/12 hours + Gentamicin 80 mg/ 8 hours for

four weeks following by 8 weeks of minocycline orally. Sensitivity to Vancomycin was also reported. As additional data, the samples from the arthroscopy were negative. In addition, given the association of this germ with bacterial endocarditis, although she was asymptomatic, an echocardiogram was performed, and endocarditis was concomitantly diagnosed. Two weeks after treatment, she started again with pain in the right hip, so xray, laboratory and hip MRI were repeated. Xray showed chondrolysis with loss of the joint space. The laboratory values were similar to those of the initial diagnosis, while MRI showed hyperintensity in the femoral head in the STIR sequence, interpreted as subchondral necrosis secondary to septic arthritis. (Figures 3-4).
We therefore decided to perform open debridement, reaming the acetabular cavity and placing an articulated custom-made spacer coated with Vancomicyn loaded cement. Two grams of Vancomycin were added to each dose of 40 grams of cement. (Figure 5).

Intraoperative, severe damage to both acetabular and femoral head cartilage was noted. The seven intraoperative samples sent to culture were negative. The patient continued the same ATB treatment, evolving favorably regarding her infectious disease.

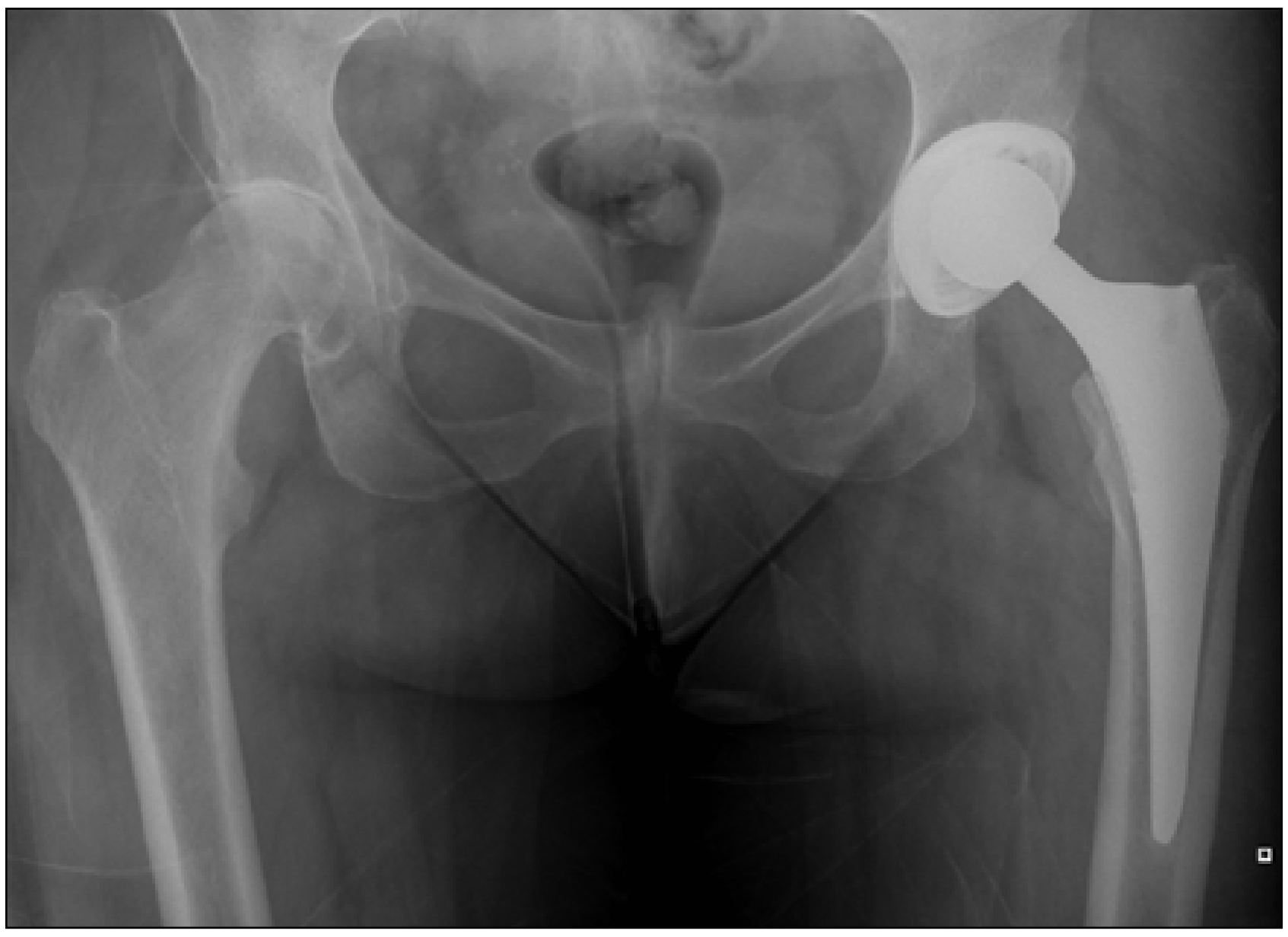

Figure 3: AP radiograph three months after the onset of symptoms shows chondrolysis with significant joint space narrowing in comparison to the previous radiograph.

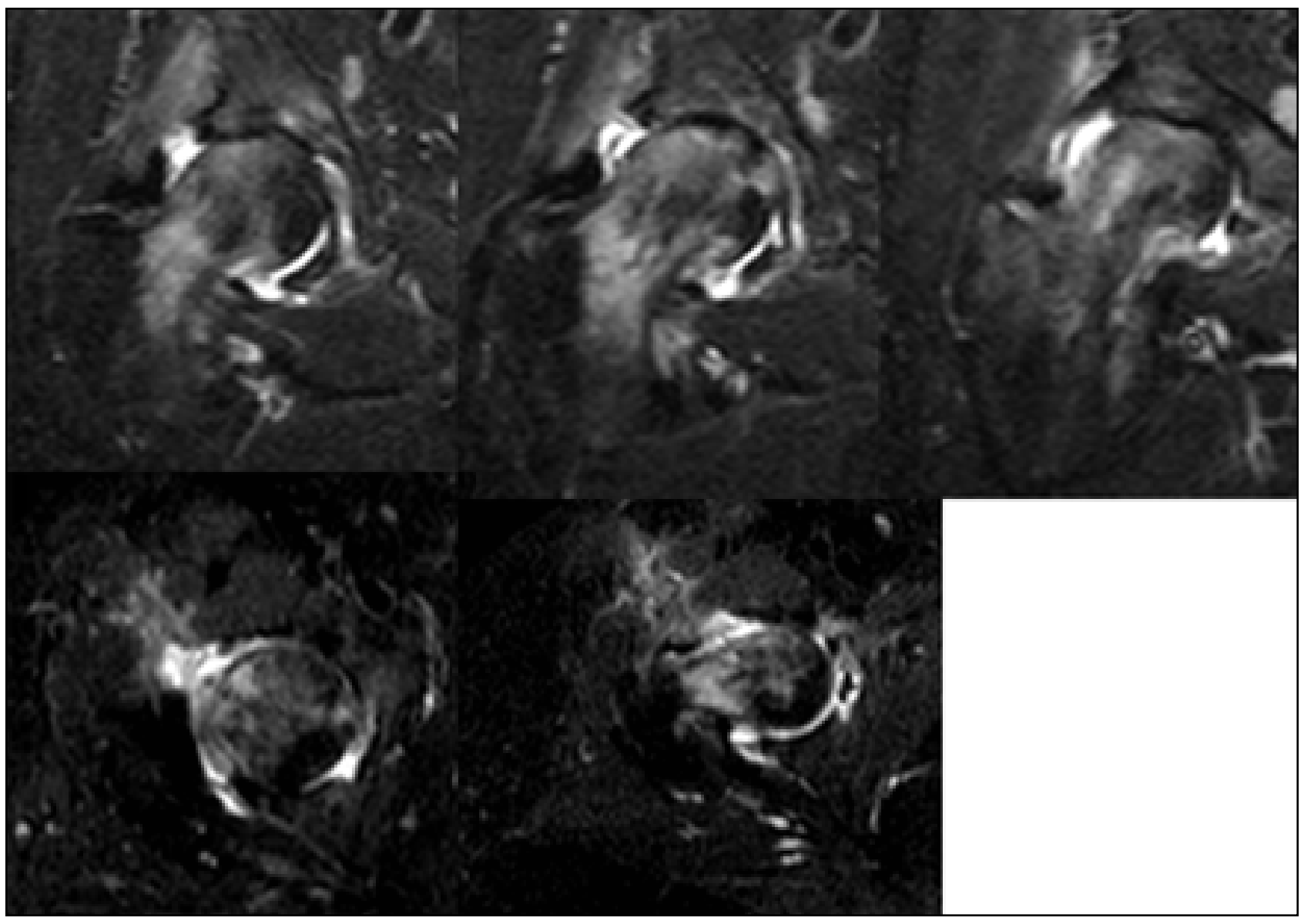

Figure 4: MRI images showed subchondral necrosis of the femoral head

Figure 5: AP radiograph showing the spacer consisting of an implant covered with vancomycin loaded cement.

At two months postoperatively, the patient is recovering uneventfully, ESR and CRP have returned to normal values and a reimplantation of a definitive THA is planned at the end of the antibiotic treatment. She is currently completing the second of three months of planned parenteral ATB treatment, walking without pain with the assistance of a cane.

DISCUSSION

Granucitella species are gram-positive anaerobic cocci, which are part of the normal flora of the upper respiratory, intestinal, urogenital, and oral tract [2]. They are facultatively anaerobic species with slow growth in standard culture media, which can cause delays in diagnosis and, consequently, treatment [2-5]. Due to their difficult growth, they often require molecular diagnostic techniques. Recently MALDI-TOF mass spectrometry was reported as a fast and accurate method of diagnosing these pathogens [5]. In the case presented, given the specific requirements for developing Granulicatella adiacens, cultures were positive after one week in blood culture bottles with pyridoxine. This specific requirement was previously reported by Shailaja et al [6].

Bone or joint infections by this germ are infrequent [1,4]. Reviewing the literature, we have found a few cases of vertebral osteomyelitis [7], periprosthetic hip infections [4,8], and the report of only one case affecting a native joint [9]. It was reported in 2003 by Hepburn et al., who reported septic arthritis of the knee in a 68-year-old woman. These authors did not highlight any risk factors for native septic arthritis, such as rheumatoid arthritis, diabetes, immunocompromised status, drug abuse, or previous surgeries [10]. In our case, septic arthritis probably originated from hematogenous dissemination from endocarditis.

Contamination following corticosteroid or hyaluronic acid injection has been reported with a risk of 1 in 1000 [10] but in our case the intraarticular steroid injection had been performed 6 weeks after the onset of symptoms.

Regarding the treatment of septic arthritis, there is no clear recommendation on the duration of ATB treatment [11]. Although this will depend on different factors, there is some consensus regarding administering at least 2-3 weeks of IV antibiotics followed by 2 to 4 weeks orally [11,12]. In the case of arthritis caused by Granulicatella adiacens, given its low frequency, there is no formal recommendation yet. Although not in native joints, Quenard et al [4]. reported 5 cases of periprosthetic infection with this germ using, in addition to surgical treatment, an ATB therapy of 180 days without reporting subsequent recurrences.

In combination with systemic ATB therapy, a recent review recommends performing serial arthrocentesis (in patients at high surgical risk), arthroscopic lavage, or open surgical debridement [11]. Regarding arthroscopic or open treatment, the literature has reported similar results [10-12]. Additionally, in chronic cases and with joint damage, staged treatment using AB-spacers is the best option [11,13]. In the case presented, we decided to perform a staged treatment with a PMMA spacer with ATB after failed arthroscopic lavage. Given the sensitivity to vancomycin obtained in the antibiogram we used primary components covered with vancomycin loaded cement. A regular polished tapered stem was used on the femoral side and a polyethylene dual mobility liner on the acetabular side. The outer aspect of this liner is smooth, so it was roughened to promote cement adherence.

To our knowledge, this is the first report of septic arthritis in a native hip caused by Granulicatella adiacens as the only infecting germ. We emphasize its association with asymptomatic endocarditis and the difficulty of its isolation in standard culture media, as well as the absence of established guidelines for its therapeutic approach. We will continue with the treatment of this patient to report the final results in the future. ■

Bibliography

1. **Portier E, Zeller V, Kerroumi Y, Heym B, Marmor S, Chazerain P. Arthroplasty after septic arthritis of the native hip and knee: retrospective analysis of 49 joints.** J Bone Joint Infect. 2022:7(2):81-90.
2. **Fukushima K, Uekusa Y, Koyama T, Ohashi Y, Uchiyama K, Takahira N, Takaso M. Efficacy and safety of arthroscopic treatment for native acute septic arthritis of the hip joint in adult patients.** BMC Musculoskeletal Disorders 2021;22(1):318.
3. **Aas JA, Paster BJ, Stokes LN, Olsen I, Dewhirst FE. Defining the normal bacterial flora of the oral cavity.** J Clin Microbiol. 2005;43(11):5721–5732.
4. **Quenard F, Seng P, Lagier JcH, Fenollar F, Stein A. Prosthetic joint infection caused by Granulicatella adiacens: a case series and review of literature.** BMC Musculoskeletal Disorders 2017;18(1):276.
5. **Seng P, Drancourt M, Gouriet F, La Scola B, Fournier P-E, Rolain JM, et al. Ongoing revolution in bacteriology: routine identification of bacteria by matrix-assisted laser desorption ionization time-of-flight mass spectrometry.** Clin Infect Dis. 2009;49(4):543–551.
6. **Shailaja TS, Sathiavathy KA, Unni G. Infective endocarditis caused by Granulicatella adiacens.** Indian Heart J 2013;65(4):447-449.
7. **Fukuda R, Oki M, Ueda A, Yanagi H, Komatsu M, Itoh M, Oka A, Nishina M, Ozawa H, Takagi A. Vertebral osteomyelitis associated with Granulicatella adiacens.** Tokai J Exp Clin Med. 2010;35(4):126–129.
8. **Badrick TC, Nusem I, Heney C, Sehu M. Granulicatella adiacens: An uncommon diagnosis of prosthetic hip joint infection. A case report with review of the literature.** IDCases 2021;25:e01204.
9. **Hepburn MJ, Fraser SL, Rennie TA, Singleton CHM, Delgado B. Septic arthritis caused by granulicatella adiacens: diagnosis by inoculation of synovial fluid into blood culture bottles.** Rheumatol Int 2003;23(5):255-257.
10. **Hassan AS, Rao AL, Manadan AM, Block JA. Peripheral bacterial septic arthritis: review of diagnosis and management.** J Clin Rheum 2017;23(8):435-442.
11. **Davis CM, Zamora RA. Surgical options and approach for septic arthritis of the native hip and knee joint.** J Arthroplasty 2020;35(3S):S14-S18.
12. **Ross JJ. Septic arthritis of native joints.** Infect Dis Clin North Am 2017;31(2):203-218.
13. **Sharff KA, Richards EP, Townes JM. Clinical management of septic arthritis.** Curr Rheumatol Rep 2013;15(6):332.

THE CHALLENGE OF TREATMENT CALCANEAL OSTEOMYELITIS:
SURGICAL OPTIONS AND OUTCOME OF A CASE SERIES

Huseyn ALIYEV[1], Chingiz ALI-ZADE[2]

1. Azerbaijan Scientific Research Institute of Traumatology and Orthopedics, Abbas Sakhhat st., 32, AZ-1007. Baku, Azerbaijan
2. HB Guven klinika, Ataturk Avenue 3078, Baku, Azerbaijan
dr.huseyn@gmail.com

INTRODUCTION

Osteomyelitis represents one of the main and most devastating complication in orthopedics. Calcaneal osteomyelitis (CO) accounts for 3–10% of all bone infections, [1, 2, 3, 20]. Schildhauer et al. (2000) quantified the calcaneal rate of infections with 11% [3, 4]. CO usually happens after trauma, post-surgery, complication of the diabetic foot and through hematogenous spread in children. Overall, Staphylococcus aureus remains the most common causative bacteria in all age groups [2, 22].

The treatment principal includes early definitive diagnosis by culture, imaging studies, blood parameters, tailored systemic antibiotic coverage, wound irrigation, wide surgical debridement, curettage, partial or total calcaneal resection with or without soft tissue coverage. When it turned into a chronic phase, treatment procedures become more difficult [2, 10, 11, 23].

The preservation of the calcaneus and a functional foot anatomy is the main target during CO treatment. This is not always possible and depending on the local situation [3]. Surgical treatment of CO currently offers only a handful of curative options including bone debridement, partial or total calcanectomy as well as below-knee amputation [20]. Following major lower extremity amputation US Centers for Disease Control data show a 1-year mortality rate of 30%, a 3-year rate of 50%, and a 5-year rate of 70%, [24, 25]. Avoidance of transtibial and transfemoral amputations is important in regard to minimizing morbidity and mortality [24, 26]. Case reports advocate the use of partial calcanectomy as a viable alternative to below knee amputation [24]. According to Lehmann et al. (2021), and Bollinger M., Thordarson D.B. (2002) partial calcanectomy represents an alternative to lower leg amputation in cases of strictly local infection [5, 6]. The authors mentioned that partial calcaneal resection may be performed if the inflammatory process involves less than 50% of the heel [7]. In these circumstances, the sufficient hind foot blood supply seems to be the central problem [8, 9].

However, the reconstruction of the resulting skeletal and soft tissue defects is often complex. In contrast to the more proximal segments of the leg, the availability of soft tissue for the coverage of full-thickness defects with local or regional flaps is limited [12, 13]. Reconstruction of skeletal defects can be accomplished with bone grafting [14]. However, large defects require complex reconstructive procedures, such as distraction osteogenesis, vascularized bone grafting, or transfer of free flaps [10, 15, 16].

In this paper the technique and outcome of a case series of CO with the concomitant use of bone and soft tissue approaches for patients diagnosed with CO are described.

MATERIALS & METHODSW

Twenty-five consecutive patients with osteomyelitis and open fractures of the calcaneus were included between 2005 and 2018. All patients were admitted to the Bone Infection Unit at our hospital under the responsibility of an orthopaedic surgeon (specializing in foot ankle surgery and bone infection surgery) who performed all operations. Patients demographics, cause of CO, previous treatment and comorbidities are summarized in table 1. Patients presented with pain (100%), swelling (100%) and purulent discharge from heels (80%). The most common causes of CO were fracture-related infection (14 patients), acute hematogenous osteomyelitis (6 patients), penetrating soft tissue trauma (2 patients) and complications after surgery (3 patients). All patients had received previous antibiotics. Sixteen patients (64%) had already undergone previous operation elsewhere. Blood parameters for WBC, ESR and CRP were elevated. Radiographs of the calcaneus showed destruction in the lesion with sclerosis of the bone tissue around the lesion. Some patients had total sclerosis of the calcaneus. Chronic CO

Sex, n (male/female)	19/6	
Age, y, mean; range	30.9 y; 5-77	
Cause no (%)	Fracture-related infection Haematogenous Penetrating soft tissue trauma Iatrogenic factor	14 (56%) 6 (24%) 2 (8%) 3 (12%)
Previous treatment no (%)	Previous antibiotics Previous surgery	9 (36%) 16 (64%)
Comorbidities no (%)	Peripheral neuropathy Peripheral vascular disease Tobacco smoker	4 (16%) 5 (20%) 13 (52%)

Table 1. Patient Demographics (n = 25)

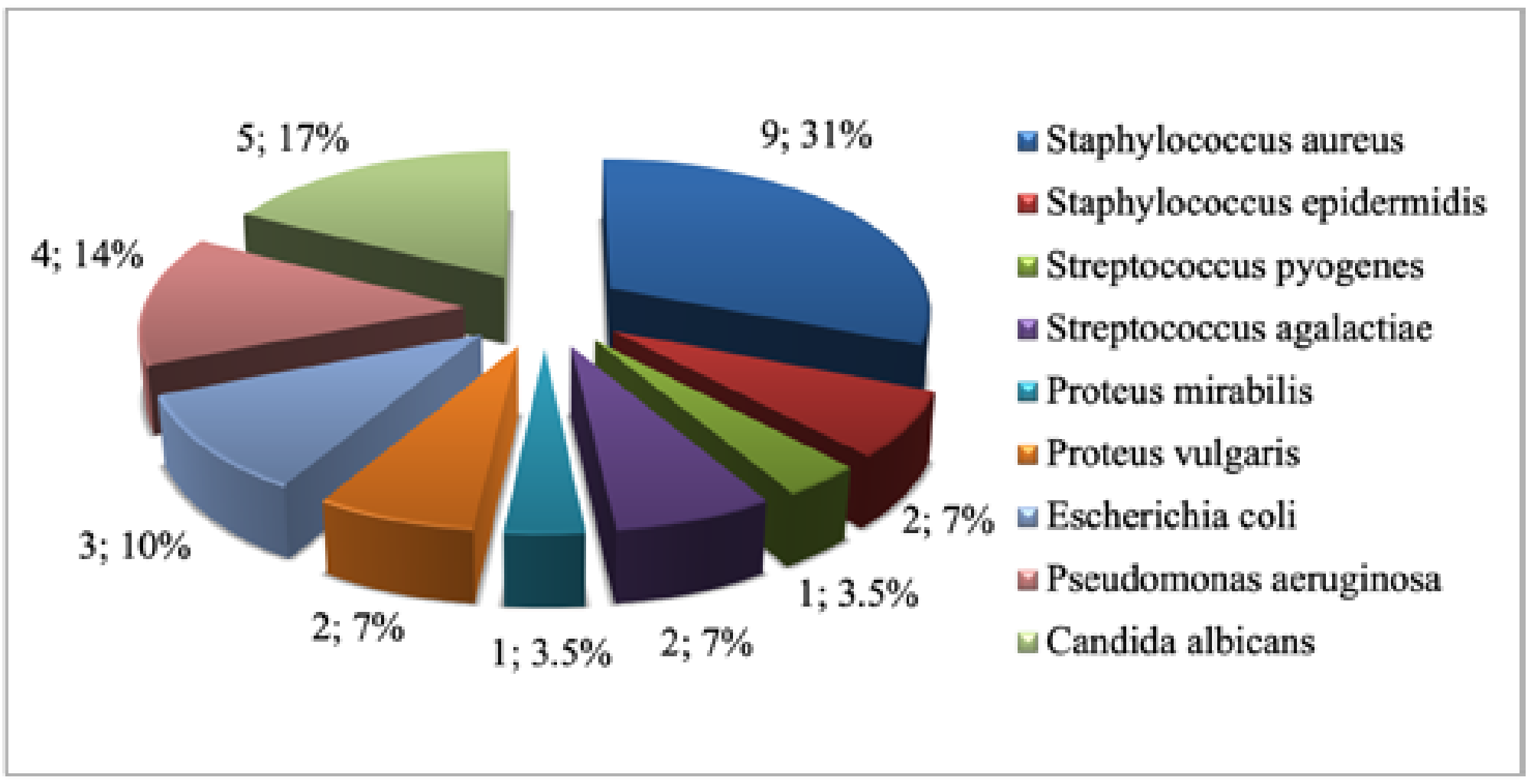

Diagram 1. Pathogens isolated from deep wound

had been diagnosed with clinical and radiograph signs of osteomyelitis for minimum 2 months, and one of the following criteria: sinus, abscess, intraoperative pus, or positive microbiological cultures from deep surgical samples.

After diagnosing CO all patients were planned for surgery under systemic antibiotic coverage. Postoperative antibiotics began empirical until appropriate bacterial culture and sensitivity results were available. The calcaneus was approached from lateral with an L shaped incision which allows good access to the infected bone and has the advantages of preserving the Achilles tendon attachment, the weight bearing surface of the calcaneus, and the overlying soft tissue. Any sinus tracts were excised and the subcutaneous and deeper soft tissues were debrided until healthy bleeding tissue planes. Thorough bone debridement or partial calcanectomy was performed and the infected bone was sent for cultures. The amount of bone debridement and excision was based on preoperative radiographs and until healthy bleeding bone remained, using curettes, cutters and osteotomes. The wound was closed either with local tissues or with one of the methods of plastic surgery. Intravenous antibiotics were continued for 1 week postoperatively followed by oral antibiotics for 1 month. All patients were seen regularly for the first 2 years after the operation, at 6 weeks, 3 months, 6 months, 1 year, and 2 years.

RESULTS

Cultures taken from the deeper aspect of the wound are summarized in Diagram 1. They included facultative anaerobe Gram-positive cocci: Staphylococcus aureus (31%), Staphylococcus epidermidis (7%), Streptococcus pyogenes (3.5%), Streptococcus agalactiae (7%); facultative anaerobe Gram-negative bacillus: Enterobactericeae family: Escherichia coli (10%), Proteus mirabilis (3.5%); Proteus vulgaris (7%); anaerobe nonfermentive Gram-negative bacillus: Pseudomonas aeruginosa (14%); form endosymbiotic fungi: Candida albicans (17%). All of the cultured microorganisms were sensitive to vancomycin and/or gentamycin (Diag.1).

All patients underwent surgery and type of bone and soft tissue management are summarized in (Table 2).

Outcomes, complications, and clinical function are summarized in table 3. Infection was successfully eradicated in 22 patients at 1-year follow-up. Wounds healed by primary intention in 18 (72%) patients. Postoperative complications occurred in 9 patients (36 %) including wound leakage in 4 patients and recurrence of the osteomyelitis process occurred in 3 patients. All of them underwent successful reoperations with necrectomy. Wounds in the plantar surface of the heel developed in 2 patients after 6 months and was not associated with recurrent osteomyelitis. After conservative treatment they have healed.

Patients stayed in the clinic for 2-4 weeks. After that, patients began to gradually load the leg for 20-30 days followed by full

Surgical technique n (%)	Trepanation Sequestrnecrectomy Necrectomy Partial calcanectomy Ilizarov apparatus	5 (20%) 13 (52%) 11 (44%) 8 (32%) 3 (12%)
Soft tissue closure n (%)	Direct closure Free skin flap Local full-thickness flaps Full-thickness flaps (the Italian method of plastics)	16 (64%) 2 (8%) 4 (16%) 3 (12%)

Table 2. Surgical techniques used

Outcome	
Recurrence of bone infection	3 (12.5%)
The wound healed by primary closure	18 (72%)
The wound healed by secondary closure	7 (28%)
30-d postoperative complications no (%)	
Wound leakage	4 (16%)
Flap revision/reexplored	3 (12%)
Superficial ulcer	2 (8 %)
Mobility, no (%)	
Unaided	22 (88%)
Crutches	3 (12%)
Footwear, no (%)	
Regular shoes	17 (68%)
Normal shoe with a molded insole	5 (12.5%)
Orthotic custom shoe	3 (7.5%)

Table 3. Postoperative outcomes

weight bearing. Most patients (88%) were able to walk unaided, and 3 (12 %) needed crutches. 17 (68%) had a foot that comfortably fit into a regular shoe. Ordinary shoes with an insole were worn by 5 patients (12.5%), 3 patients wore a custom-made shoe (7.5%). Mild weight bearing pain was in 3 patients, 22 reported being pain free (Table 3).

CLINICAL CASE

A 59-year-old male patient was admitted with pain in the right calcaneus. More than 2 years ago, he had an open fracture of the right calcaneus with wound healing problems and a fistula one month after surgery.

Diagnosis: *chronic post-traumatic osteomyelitis of the right calcaneus.*
Operation: Longitudinal osteotomy of the right calcaneus, intralesional resection to healthy tissues. Primary wound healing and after 2 months full weight bearing. x-rays at 6 months show a healed bony lesion and no complaints (Figure 1).

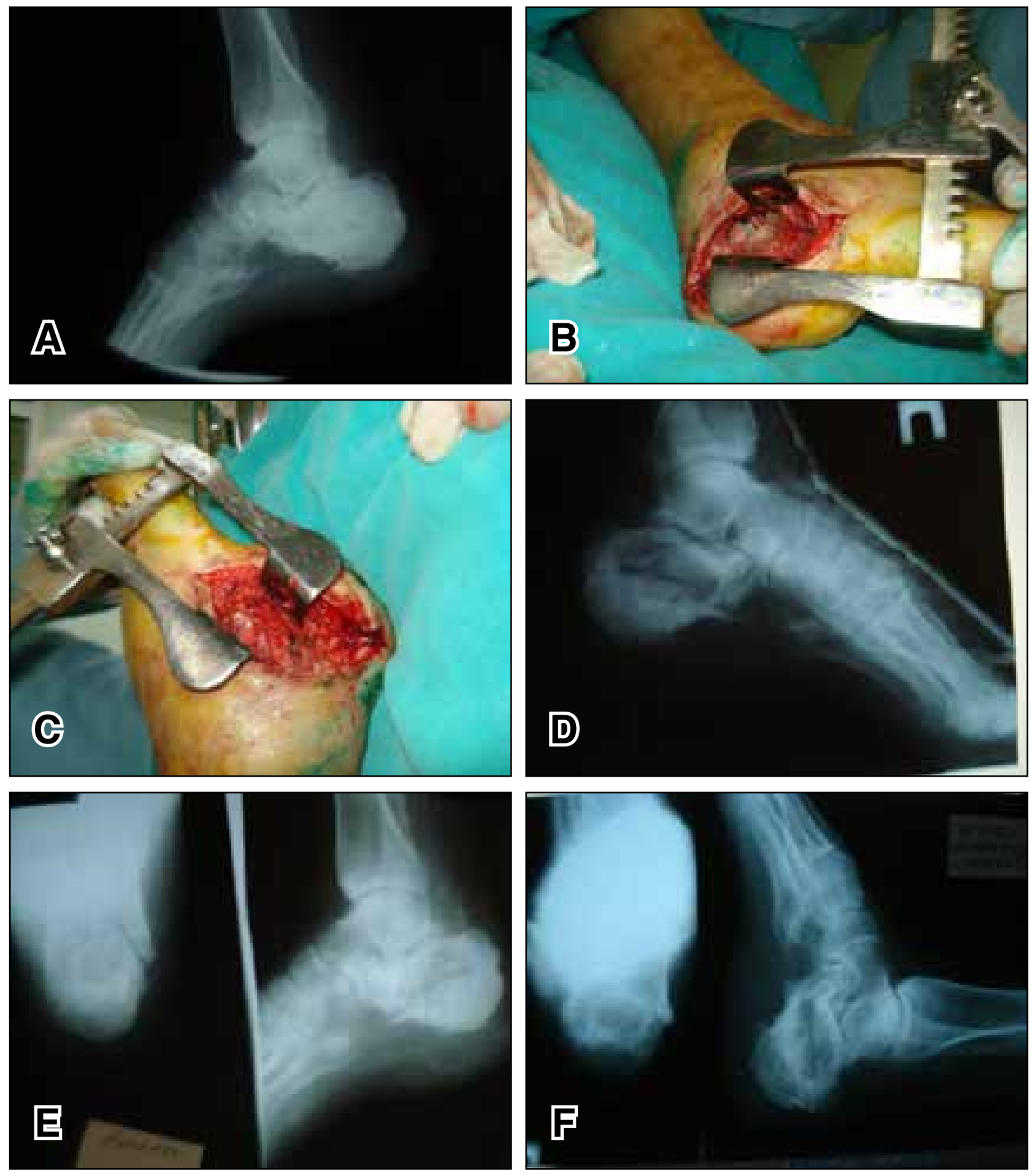

Figure 1: (A) X-ray of the right calcaneus before surgery. (B) intraoperative photographs after longitudinal osteotomy. (C) after intralesional resection. (D) x-ray after surgery. (E) x-ray after 2 months. (F) x-ray at 6 months-F.

DISCUSSION

Osteomyelitis of the calcaneus is a challenge for the patient and the surgeon. Generally, the goal of treatment includes eradication of infected bone, ensuring skeletal stability, adequate soft tissue coverage and preservation of function of the foot. Surgical management of CO includes local curettage or partial calcanectomy or total calcanectomy. In more severe cases of extensive calcaneal involvement, limited soft tissue coverage creates a challenge for the surgeon to allow for primary closure. Excision of devascularized infected bone risks destroying the weight bearing plantar cortex, detaching the Achilles tendon and disrupting the hindfoot complex. Moreover, in cases of osteomyelitis, the overlying plantar fat pad and skin are often compromised and limit soft tissue closure. Often below knee amputation has been recommended in these cases [20, 31, 36, 37, 38, 40, 41].

Only 3 (12.5%) patients in our study had a recurrence of bone infection which was similar to those of previous studies [40, 42, 43, 44]. Complications occurred in 9 cases (36%) including local ulcer, aseptic wound leakage and partial skin necrosis which needed 3 reoperations. Multiple further cohort series of partial, subtotal, and total calcanectomies have been published with varying results. One systematic review reports 80% healing rates, with better results occurring with partial rather than total calcanectomies [21, 27, 31]. Another systematic review found that 85% of patients receiving a partial calcanectomy maintained their mobility levels [31, 39]. Partial calcanectomy is a relatively simple procedure for chronic heel ulcers with limited calcaneal involvement. The amount of soft tissue compromise may allow for primary closure following partial calcanectomy [20, 31, 36].

Whether bone infection relapses after treatment is influenced by multiple factors, such as surgical strategies, pathogen species and virulence and finally, host immune status. The goal of operations is to remove all the devitalized infected tissues, leaving behind healthy vascularized bone. It is reasonable to understand that the protocols for CO treatment include partial and total calcanectomy, or even below-knee amputation. Although infection can be eradicated following such radical surgeries, the foot function may be more or less impaired [40, 45, 46].
If a primary wound closure is not possible it can be achieved by various plastic procedures including free muscle flaps (serratus anterior, gracilis), or local flaps (rotational flaps, abductor digiti minimi flap, neurocutaneous or fasciomusculocutaneous flaps). Skin grafting with a rotational flap using local tissues (Qarris and Saad method) was performed in 4 patients, wounds in 2 patients were closed with free split skin flaps. The reviewed studies showed no difference in the reinfection rate and failure rate of the flaps. However, the choice of soft tissue coverage should be based on the location and size of the soft tissue defect. Direct closure with the adjacent normal skin is preferable, but small defects may be reliably covered by local pedicle flaps [1, 47]. Disadvantages of free vascularized flaps are the need of microsurgery, long operation time, and prolonged hospital stay combined with higher costs. They are also usually insensate, producing a later risk of pressure ulceration. Regardless of which coverage is used, the applied procedure should guarantee an improved bone vascularization and a good dead

Cairo, Egypt

SICOT

43rd SICOT ORTHOPAEDIC WORLD CONGRESS

21 - 23 November 2023

Combined meeting with the Egyptian Orthopaedic Association space management to avoid haematoma formation [1, 48].

Despite the presence of various microorganisms in the formation of CO, gram-positive bacteria play a major role. In our study staphylococcus strains were the more common with 38 %. The majority were coagulasopositive Staphylococcus aureus with 31% which might occur in single and associative forms. Similar results were observed by many authors [2, 22, 31, 32].

Candida albicans were observed in 17 % which needed long term AB therapy. Patients without infection eradication may be caused by ineffective antibiotic therapy, difficulties in the surgical treatment and adverse effects. Other authors observed similar results [32, 33, 34, 35].

Seven pediatric patients (mean age 10.3 years, range 5-16) with chronic CO were treated with trepanation of the calcaneus with intralesional resection from the lateral incision.

A recurrence of the osteomyelitic process was observed in 1 patient. He underwent another successful necrectomy. Osteomyelitis in children is a potentially dangerous disease that requires early diagnosis and treatment in order to prevent the spread of infection to nearby joints, bone growth disorders and reduced quality of life [17, 19]. Nevertheless, acute osteomyelitis is not always easy to recognize since bone pain without systemic signs and symptoms, negative imaging and blood tests may confuse the clinician [18]. This is especially true when small bones, like the calcaneus, are involved. In this case, signs and symptoms may be even more subtle. Therefore, clinical experience and high index of suspicion are necessary for the emergency pediatrician to recognize and promptly treat these conditions [17].

CONCLUSION

Chronic osteomyelitis of the calcaneus is a disease that threatens the limb. Treatment of CO can be complex due to the poor soft tissue coverage and the nature of the stress on the calcaneus. CO is difficult to manage and requires a multidisciplinary approach involving orthopaedic surgeons, plastic surgeons and infectious diseases physicians. More than 30% of microbiological data showed the presence of staphylococcus aureus, which must be taken into account in antibiotic therapy at the beginning of treatment. Our results also show that using a single-stage partial resection of calcaneum with primary closure of wound is a viable and useful technique in managing CO. ■

Bibliography

1. **Sabater-Martos M., Sigmund I.K., Loizou C., McNally M. Surgical treatment and outcomes of calcaneal osteomyelitis in adults: A systematic review.** J Bone Jt Infect. 2019;4:146-54. doi: 10.7150/jbji.34452

2. **Agrawal A.C., Ojha M.M., Garg D.K., Pandiyarajan E. Calcaneal Osteomyelitis Treated with Antibiotic Mixed Calcium Sulphate Pellets. A Case Report.** Journal of Orthopaedic Case Reports 2021 October: 11(10): Page 81-83.

3. **Yoohak Kim et al. A Case of Osteomyelitis after Calcaneal Fracture Treated by Antibiotic-Containing Calcium Phosphate Cements.** Hindawi, Case Reports in Orthopedics, Volume 2018, Article ID 9321830, 4 pages, https://doi.org/10.1155/2018/9321830

4. **Schildhauer T.A., Bauer T.W., Josten C., Muhr G. "Open reduction and augmentation of internal fixation with an injectable skeletal cement for the treatment of complex calcaneal fractures,"** Journal of Orthopaedic Trauma, 2000. vol. 14, n°5, pp. 309–317.

5. **Lehmann S., Murphy R.D., Hodor L. "Partial calcanectomy in the treatment of chronic heel ulceration,"** Journal of the American Podiatric Medical Association, 2001,vol. 91, n° 7, pp. 369–372,.

6. **Bollinger M., Thordarson D.B. "Partial calcanectomy: an alternative to below knee amputation,"** Foot & Ankle International, 2002.vol. 23,n°10, pp. 927–932,

7. **Baumhauer J.F., Fraga C.J., Gould J.S., Johnson J.E. "Total calcanectomy for the treatment of chronic calcaneal osteomyelitis,"** Foot & Ankle International, 1998, vol. 19, n°12, pp. 849–855.

8.**Smith D.G. "Principles of partial foot amputation in the diabetic,"** Foot and Ankle Clinics, 1997, vol. 2, n°1, pp. 171–186,.

9. **Weinfeld S.B., Schon L.C. "Amputation of the perimeters of the foot,"** Foot and Ankle Clinics, 1999, vol. 4, no. 1, pp. 17–37,. https://doi.org/10.1155/2018/9321830

10. **Patzakis M.J., Zalavras C.G. "Chronic posttraumatic osteomyelitis and infected nonunion of the tibia: current management concepts," The** Journal of the American Academy of Orthopaedic Surgeons, vol. 13, n°6, pp. 417–427, 2005.

11. **Zarutsky E., Rush S.M., Schuberth J.M. "The use of circular wire external fixation in the treatment of salvage ankle arthrodesis,"** The Journal of Foot and Ankle Surgery, vol. 44, n°1, pp. 22–31, 2005.

12. **Baumeister S., Germann G. "Soft tissue coverage of the extremely traumatized foot and ankle,"** Foot and Ankle Clinics, vol. 6, n°4, pp. 867–903, 2001.

13. **Levin L.S. "Soft tissue coverage options for ankle wounds,"** Foot and Ankle Clinics, vol. 6, no. 4, pp. 853–866, 2001.

14. **Zalavras C.G. Patzakis M.J., Thordarson D.B., Shah S., Sherman R., Holtom P. "Infected fractures of the distal tibial metaphysis and plafond,"** Clinical Orthopaedics and Related Research, vol. 427, pp. 57–62, 2004.

15. **Keating J.F., Simpson A.H.R.W., Robinson C.M. "The management of fractures with bone loss,"** The Journal of Bone and Joint Surgery British 2005,vol.87-B, n°2, pp. 142–150.

16. **Malizos K.N., Zalavras C.G., Soucacos P.N., Beris A.E., Urbaniak J.R. "Free vascularized fibular grafts for reconstruction of skeletal defects,"** The Journal of the American Academy of Orthopaedic Surgeons, 2004, vol. 12, n°5, pp. 360–369.

17. **Buonsenso D., Pata D., Masiello E., Salerno G., Valentini P. Calcaneal Osteomyelitis with Persisting Negative X-Rays and Blood Tests.** Journal of Case Reports: Clinical & Medical. 2019; 2(3):137.

18. **Jaakkola J., Kehl D. Hematogenous calcaneal osteomyelitis in children.** J Pediatr Orthop. 1999; 19: 699–704.

19. **Rasool M.N. Hematogenous osteomyelitis of the calcaneus in children.** J Pediatr Orthop. 2011; 21: 738–743.

20. **Saxon A.J., Verdin C., Nicolosi N. Calcanectomy for the Treatment of Osteomyelitis in a Patient with a Chronic Calcaneal Fracture: A Case Report.** The Northern Ohio Foot & Ankle Foundation Journal, 2020, Vol. n°1.

21. **Yammine K., El-Alam A., Assi C. (2021) Outcomes of partial and total calcanectomies for the treatment of diabetic heel ulcers complicated with osteomyelitis. A systematic review and meta-analysis.** Foot Ankle Surg 2021;27(6): 598–605. doi: 10.1016/j.fas.2020.07.014.

22. **Chen K., Balloch R. Management of calcaneal osteomyelitis.** Clin Podiatr Med. Surg. 2010; 27:417-29.

23. **McCann M.J., Wells A. Calcaneal osteomyelitis: Current treatment concepts.** Int J Low Extrem Wounds 2020; 19:230-5.

24. **Gangopadhyay P., Scot Malay D. Limb salvage in the setting of calcaneal osteomyelitis and pathologic fracture: A case report with a 15-year follow-up.** Foot & Ankle Surgery: Techniques, Reports & Cases 1 (2021) 100023 https://doi.org/10.1016/j.fastrc.2021.100023

25. **Centers for Disease Control and Prevention. National diabetes fact sheet: general information and national estimates on diabetes in the United States, 2005. Atlanta, GA:** US Dept. of Health and Human Services, Centers for Disease Control and Prevention; 2005.

26. **Walsh T.P., Yates B.J. Calcanectomy: avoiding major amputation in the presence of calcaneal osteomyelitis-A case series.** The Foot. 2013; 23:130–135.

27. **Wokhlu A., Vasukutty N. Partial calcanectomy with antibiotic biocomposite injection for diabetes patients with heel ulcers and calcaneal osteomyelitis: a single-stage treatment.** The Diabetic Foot Journal 2021, Vol 24 No 3, p. 34-37.

28. **Oliver N.G., Steinberg J.S., Powers K. et al. (2015) Lower extremity function following partial calcanectomy in highrisk limb salvage patients.** J Diabetes Res 2015: 432164.

29. **McNally M., Govaert G., Dudareva M., Morgenstern M., Metsemakers W.J. Definition and diagnosis of fracture-related infection.** EFORT Open Rev. 2020; 5(10):614-619. doi: 10. 1302/2058-5241.5.190072

30. **McNally M.A., Ferguson J.Y., Lau A.C., et al. Single-stage treatment of chronic osteomyelitis with a new absorbable, gentamicin-loaded, calcium sulphate/hydroxyapatite biocomposite: a prospective series of 100 cases.** Bone Joint J. 2016; 98- B (9):1289-1296. doi: 10.1302/0301-620X.98B9.38057

31. **Kendal A., Loizou C., Down B., McNally M. Long-term follow-up of complex calcaneal osteomyelitis treated with modified Gaenslen approach.** Foot & Ankle Orthopaedics 2022, Vol. 7(4) 1–9.

32. **Aliyev H., Rasulova G., Ali-Zade Ch., Benzakour T., Romano C.L., Drago L. Septic Arthritis of the Knee Joint. A 5-year Retrospective microbiology investigation.** MO-Journal N°18 – July/August 2022. https://mo-journal.com/posts/septic-arthritis-of-the-knee-joint-in-azerbaijan-a-5-year-retrospective-microbiological-investigation-1787

33. **Khudayberganova Sh.A., Murodov T.R., Khodzhaev K.Sh., Yusupova S.I., Tuyunbayeva L.Sh. Significance of microflora monitoring in a surgical hospital.** Wounds and wound infections. Materials of the I International Congress. Moscow, 2012, pp. 341-342.

34. **Fraimow H.S., Tsigrelis C. Antimicrobial resistance in the intensive care unit: mechanisms, epidemiology, and management of specific resistant pathogens.** Critical care clinics 2011, Vol. 27, n°1, pp. 163–205.

35. **Magiorakos A.P., et al. Multidrug-resistant, extensively drug-resistant and pandrug-resistant bacteria: an international expert proposal for interim standard definitions for acquired resistance.** Clinical microbiology and infection: the official publication of the European Society of Clinical Microbiology and Infectious Diseases 2012, Vol. 18, n°3. pp. 268–281.

36. **Kendal A.R., Ferguson J., Wong T.H.N., Atkins B.L., McNally M. Osteomyelitis - symptoms, diagnosis and treatment. BMJ Best Practice Update. BMJ Best Pract. April 7, 2021.**

37. **Huang K., Guo Q.F., Zhu Y.S. The epidemiology and clinical features of calcaneus osteomyelitis following calcaneus fracture: a retrospective study of 127 cases. Ann Palliat Med. 2021; 10(3):3154-3161. doi: 10.21037/apm-21-208**

38. **Iacobucci G. One in 10 UK adults could have diabetes by 2030, warns charity.** BMJ. 2021; 375:n2453.

39. **Schade V.L. Partial or total calcanectomy as an alternative to below-the-knee amputation for limb salvage: a systematic review.** J Am Podiatr Med Assoc. 2012; 102(5):396-405. doi: 10.7547/1020396.

40. **Jiang N., Zhao X.Q., Wang L., Lin Q.R., Hu Y.J., Yu B. Single-stage debridement with implantation of antibiotic-loaded calcium sulphate in 34 cases of localized calcaneal osteomyelitis.** Acta Orthopaedica 2020; 91 (3): 353–359.

41. **Mooney M L, Haidet K, Liu J, Ebraheim N A. Hematogenous calcaneal osteomyelitis in children.** Foot Ankle Spec 2017; 10(1): 63-8.

42. **Ferguson J.Y., Dudareva M., Riley N.D., Stubbs D., Atkins B.L., McNally M.A. The use of a biodegradable antibiotic-loaded calcium sulphate carrier containing tobramycin for the treatment of chronic osteomyelitis: a series of 195 cases.** Bone Joint J 2014; 96-B (6): 829-36.

43. **Ferguson J., Diefenbeck M., McNally M. Ceramic biocomposites as biodegradable antibiotic carriers in the treatment of bone infections.** J Bone Jt Infect 2017; 2(1): 38-51.

44. **Luo S., Jiang T., Yang Y., Yang X., Zhao J. Combination therapy with vancomycin-loaded calcium sulfate and vancomycin-loaded PMMA in the treatment of chronic osteomyelitis.** BMC Musculoskelet Disord 2016; 17(1): 502.

45. **Metsemakers W.J., Kuehl R., Moriarty T.F., Richards R.G., Verhofstad M.H. J., Borens O., Kates S., Morgenstern M. Infection after fracture fixation: current surgical and microbiological concepts.** Injury 2018a; 49(3): 511-22.

46. **Waibel F.W.A., Klammer A., Gotschi T., Uckay I., Boni T., Berli M.C. Outcome after surgical treatment of calcaneal osteomyelitis.** Foot Ankle Int 2019; 40(5): 562-7.

47. **Boffeli T.J., Collier R.C. Near total calcanectomy with rotational flap closure of large decubitus heel ulcerations complicated by calcaneal osteomyelitis.** J Foot Ankle Surg. 2013;52(1):107-112.

48. **Attinger C., Cooper P. Soft tissue reconstruction for calcaneal fractures or osteomyelitis.** Orthop Clin North Am. 2001;32(1):135–170.

TREATMENT OF POST INFECTION TIBIA BONE DEFECTS WITH ILIZAROV EXTERNAL FIXATION

ALGORITHMIC APPROACH AND RESULTS OF A CASE SERIES

Mohamed FADEL[1], Mohamed Ahmed ABDELKADER[2] , Issam Hozayen AZIZELDIN SAIF[3], Mostafa Mahmoud AHMED[4] , Tarek ALMEGHALLAWY[5] , Haitham Ahmed ELWAKIL[6] , Shawkat Ghazal HAFEZ[7]

1. Minia university hospital, Program Director, WAIOT Director of Africa, Egypt
2. Beni-suef University, Egypt
3. Sharjah University UEA
4. Police Hospital, Egypt
5. Damietta General Hospital, Egypt
6. Almana General Hospital, Dammam, Saudi Arabia
7. Cairo Egypt

fadelminia@yahoo.com

INTRODUCTION

Infected bone defects represent one of the most difficult and challenging conditions to treat in orthopedic trauma. Successful treatment requires appropriate preoperative workup and a staged approach to surgical management. Preoperative workup should consist of imaging and laboratory studies (white blood cell counts, erythrocyte sedimentation rate, and C-reactive protein). In addition, patients should be investigated and treated for any nutritional or metabolic deficiencies, immune compromise and other comorbidities impacting healing. The initial surgical stage is focused on eradication of infection with a combination of surgical and antibiotic treatment.

Many different approaches for management of leg bone defects are described and various techniques have been developed to address this issue [1,2]. The Ilizarov external Fixator (IEF) is a revolutionary technique that involves the use of a circular external fixator to stabilize the limb, lead to bone union, and address malalignment, leg length discrepancy, and soft tissue defects [1,3]. This method has been used to treat fractures, nonunions, deformities, and other bone defects. Although bone defects treated by IEF have reached satisfactory outcomes in most studies, there were still some unsatisfactory results with relatively high complications reported in some studies [1,4]. Other methods have also been developed to manage leg bone defects, such as the vascularized fibular graft and the induced membrane (Masquelet) technique. These methods have shown promising results in terms of faster healing, shorter external fixation time, and lower complication rates. However, they also have their own limitations and drawbacks [5].

In the first part of this paper the treatment with IEF will be described together with a simple classification of bone defects, derived from our practical experience. This might allow rapid diagnostic criteria for middle-income (LMIC) countries. In the second part we will report on a case series using this classification system in combination with IEF technique.

PRIMARY TREATMENT GOALS

1. Removal of all loose or chronically infected hardware.
2. Debridement of all infected or nonviable bone and soft tissue.
3. Multiple deep tissue biopsies for culture and sensitivity to guide antibiotic treatment (minimum of 3–5 specimens).
4. Revision of fracture fixation (using either temporary or permanent fixation).
5. Placement of local antibiotic treatment if possible.
6. Soft tissue management as required (e.g, primary closure, vacuum-assisted closure, or flap coverage) [9].

EVALUATION OF BONE DEFECTS

Classification according to size of bone defect [10]:

- Group 1: bone defect less than 2 cm.
- Group 2: bone defect from 2- 6 cm.
- Group 3: bone defect from 6- 12 cm.
- Group 4: bone defect more than 12 cm.

We find the above classification, very detailed and of valuable results in research and well qualified center, as well as limb reconstructive surgery (LRS) specialized unites. To facilitate bone defect classification for resident, junior orthopedic specialist in LMICs, we prefer to separate into 2 groups only according to bone defect sizes:

Small defects (<3 cm):

Defects less than 15 mm may be left to heal by obliterating the defect through shortening the limb to facilitate contact between the bone ends and subsequent union. The shortened limb may then be managed by orthotic means or not at all if less than 15 mm. However, larger defects towards 3 cm may be amenable to management by bone grafting after the soft tissues have recovered well or using the Masquelet technique as a planned procedure. IEF is another option to close the defect and provide early weight bearing tool.

Large defects (>3 cm):

Regarding the bone defects more than 3 cm, the defect area has to be debrided and all necrotic and dead tissue are removed. The bone is explored and debrided and infected or necrotic edge of the bone are removed. In patients with infected bone defect sites, we applied antibiotic locally or used Masquelet-induced membrane technique until laboratory and clinical evidence of healthy noninfected bone gap area is confirmed. IEF has its merits to reconstruct the bone defect even associated with soft tissue loss.

EVALUATION OF SOFT TISSUE DEFECTS

Some of these cases represent soft tissues defects which need specific procedures which can be classified in 3 types (Table 1).

• ***Type alpha:*** No soft tissue deficit. No additional soft tissue reconstruction is required before or following bony reconstructive procedures.

• ***Type beta:*** Soft tissue defects which require soft tissue reconstruction
The soft tissue envelope will need augmentation to support the underlying bony reconstruction which are higher up on the reconstruction ladder including random, axial and free flaps.

• ***Type gamma:*** Unable to reconstruct the soft tissue defect [10].

Negative-pressure wound therapy (NPWT) also known as vacuum-assisted closure (VAC) was initially viewed as a revolution in wound management to the extent a new reconstructive ladder incorporating NPWT was proposed [11]. Advantages of NPWT included an increased rate of granulation tissue formation, decreased peri wound oedema, decreased time to wound closure, less frequent dressing changes, control of bacterial proliferation and potential financial advantages [12].

HOST OPTIMIZATION

This should also be included into the management and can be determined according to the host type (Modified McPherson) [13]. The importance of host optimization during limb reconstruction surgery cannot be emphasized enough. The host status serves as the primary indicator of the patient's ability to affect the healing of bone and soft tissues, as well as their ability to launch an effective immune response against infection.

- **Type A**: Good immune system and delivery.
- **Type B**: Compromised locally (BL) or systemically (BS).
- **Type C**: Requires no treatment; minimal disability; treatment worse than the disease; not a surgical candidate.

Soft tissue defect type	Host category	Bone defect size			
		< 2cm	2-6cm	6-12cm	>12cm
alpha	A	Primary bone grafting with internal fixation	Masquelet with primary internal fixation or non-vascularized graft	Acute and gradual shortening and lengthening with Ilizarov fixator trifocal or Masquelet with primary internal fixation or fibula graft in a child or upper limb defects	Acute and gradual shortening and lengthening with Ilizarov fixator or vascularized fibula graft or Masquelet with primary internal fixation
	B	Shortening	Acute and gradual shortening and lengthening with Ilizarov fixator bifocal	Acute and gradual shortening and lengthening with Ilizarov fixator Trifocal	Acute and gradual shortening and lengthening with Ilizarov fixator
beta	A	Acute shortening/flap for wound management or Masquelet induced membrane technique	Masquelet-induced membrane technique or open bone transport	Bone transport through the induced membrane or Masquelet-induced membrane technique	Osteo-myo-cutaneous vascularized fibula graft in upper limbs or Bone transport through the induced membrane
	B	Acute shortening for wound healing/flap and fixation by Ilizarov	Open bone transport or bone transport through the induced membrane	Open bone transport or bone transport through the induced membrane	Consider amputation in type B and C host
gamma	A	Convert a gamma to beta/alpha wound, bony stabilization with ex-fix	Convert a gamma to beta/alpha wound, bony stabilization with ex-fix	Convert a γ to β/α wound, bony stabilization with ex-fix	Convert a γ to α wound, bony stabilization with ex-fix Consider amputation
	B	Make every effort to convert a B to A host and a gamma to beta or alpha wound	Make every effort to convert a B to A host and a gamma to beta or alpha wound	Consider amputation, especially in C host	Consider amputation in type B and C host

Table 1 shows the combined approach for soft tissue defect types and bone defect sizes for the management of Segmental Bone defects [10]

ROLE OF BIOLOGICS IN BONE DEFECT MANAGEMENT

The ability to augment the treatment of bone defects with biologic materials or strategies represents an attractive alternative to conventional treatment options. Several biologic materials or treatments are currently available for use including cellular therapies with bone marrow aspirate, platelet-rich plasma (PRP), BMP, and distraction osteogenesis [14].

Bone marrow aspirate concentrate

Concentrated bone marrow aspirate contains a viable population of osteoprogenitor cells that can participate in osteogenesis. This material has been combined with multiple different adjuvants or composites that serve as osteoconductive carriers to deliver the osteogenic marrow elements. This represents a single-step biological strategy for bone defect management. Marrow progenitor cells are harvested from the iliac crest, concentrated in the operating room, and seeded onto an osteoconductive substrate with a microporous structure that provides the cells with a potentially stable and well-vascularized environment. This osteogenic construct is then implanted into the defect. Scaffolds used include particulate demineralized bone matrix (DBM), collagen sponges, and porous hydroxyapatite ceramics.

Platelet rich plasma (PRP)

Currently, there is no Level I evidence to indicate that using PRP alone or in combination with other materials has a substantial effect on bone healing. The available evidence (Levels III and IV) indicates that PRP may have a positive effect as an adjunct to local bone graft, and its use has been suggested to increase the rate of bone deposition and improve the quality of bone regeneration and fusion in nonunion situations.

Bone morphogenetic proteins (BMP)

The use of inductive proteins (BMPs) has been approved for open tibial shaft fractures and has demonstrated encouraging results for the reconstruction of segmental defects. Jones et al used BMP-2 combined with allograft bone for the treatment of acute segmental tibial defects and compared this with a group treated with autograft alone. In this Level 1 clinical trial, the average defect size was 4 cm (up to 7 cm). There were no significant differences in complication rates or functional outcomes between the 2 groups, with similar union rates noted. This study suggested that rhBMP-2/allograft is safe and as effective as autogenous bone grafting for the treatment of tibial defects [14].

ROLE OF IEF IN BONE AND SOFT TISSUE RECONSTRUCTION

Ilizarov external fixator (IEF) is helpful and malleable procedure for bone defect fixation. To close the different sizes of bone defect, IEF can be applied with different strategies. This includes acute compression in some cases, acute compression followed by distraction compensating lengthening, gradual compression followed by distraction, corticotomy compensating lengthening from the healthy metaphyseal region, bone transport using gradual compression with distraction at the corticotomy site, bone transport using gradual compression with distraction at 2 corticotomy sites, free vascularized fibular graft, free non-vascularized fibular graft and Ilizarov assisted fibula transportation were used. One of its merits, IEF might be used to compensate the bone defect as well as the soft tissue defects.

REPORT OF A CASE SERIES USING IEF TECHNIQUE

This study includes bone defects due to infected nonunion of tibia in patients treated between September 2015 and 2020 in our hospitals.

Patients and Methods

43 cases (6 females) of post traumatic bone defect due to infected tibia shaft with average age 30 years (range: 18- 62) were included. History of infection was less than 6 months in 8 patients. All had failed previous surgical attempts for management of bone defects pre or post debridement. There was history of more than 2 previous surgical attempts for management in all cases. Patients presented with discharging sinus in 27 cases, intermittent discharging sinus in 8 cases. Nonunion was associated with stiff ankle in 21 cases. All treated 43 cases were followed for at least two years (24-36 months).

Surgical Technique

The wound was debrided, and excision of the sinus was performed. The bone was explored, debrided, sequestrectomy was performed, and local antibiotic was added, if financially possible.

To close different sizes of defects, different IEF techniques were used :

- **Osteotomy** was performed percutaneously using multiple drills and an osteotome for lengthening or bone transport technique at metaphyseal area proximally or distally if bone or soft tissue permitted. In most cases, early guided weight bearing and independent walking using crutches had been performed. Bone healing and functional results were assessed according to ASAMI criteria (Association for the Study and Application of the Method of Ilizarov) and according to Paley's classification for complications [7].

- ***Monofocal technique in 14 cases:***
  - 4 Patients (defect 3 cm or less) accepted acute docking and union with shortening 3 cm or less.
  - 6 Patients (defect 3 cm or less) did not accept any discrepancy from other limb length, treated by acute shortening, followed by gradual lengthening, from the same site of bone defect, to attain the discrepancy of 3 cm and less.
  - 4 Patients (defect 3 cm or less) did not accept any discrepancy from other limb, treated by Masquelet technique.

- ***Bifocal bone transport in 21 patients*** (one with acute docking).

- ***Trifocal bone transport*** in 1 patient.

- ***Free vascularized fibular graft*** in 1 patient.
- ***Free non-vascularized fibular graft*** in 3 patients.

- ***Ilizarov assisted reconstruction of comminuted and soft tissue traction of lower 1/3 leg bones*** in 1 patient (Fig 1).
- ***Fibula Ilizarov assisted technique*** in 2 patients (Fig 2).

Outcomes

All nonunion sites united, and soft tissue healed between 6 and 15 months. Complete consolidation of the regenerate bone was obtained within an average of 8.8 weeks.

Complications

Ten limbs with mild intermittent discharging sinus needed continued local dressing and antibiotics, and 6 limbs re-debridement had to be performed but all finally healed. Further complications included pin tract infection in 9 cases, ankle stiffness in 15 cases and refracture after frame removal in one case. The complications did not preclude the surgical outcome.

CONCLUSION

Ilizarov external fixator is effective in management of bone defect pre or post debridement of infected nonunion of the tibia shaft. It provides advantages of many variable technique with Ilizarov application. Acute docking, lengthening, and correction of deformity could be practiced if needed, in the same procedure, with early rehabilitation.

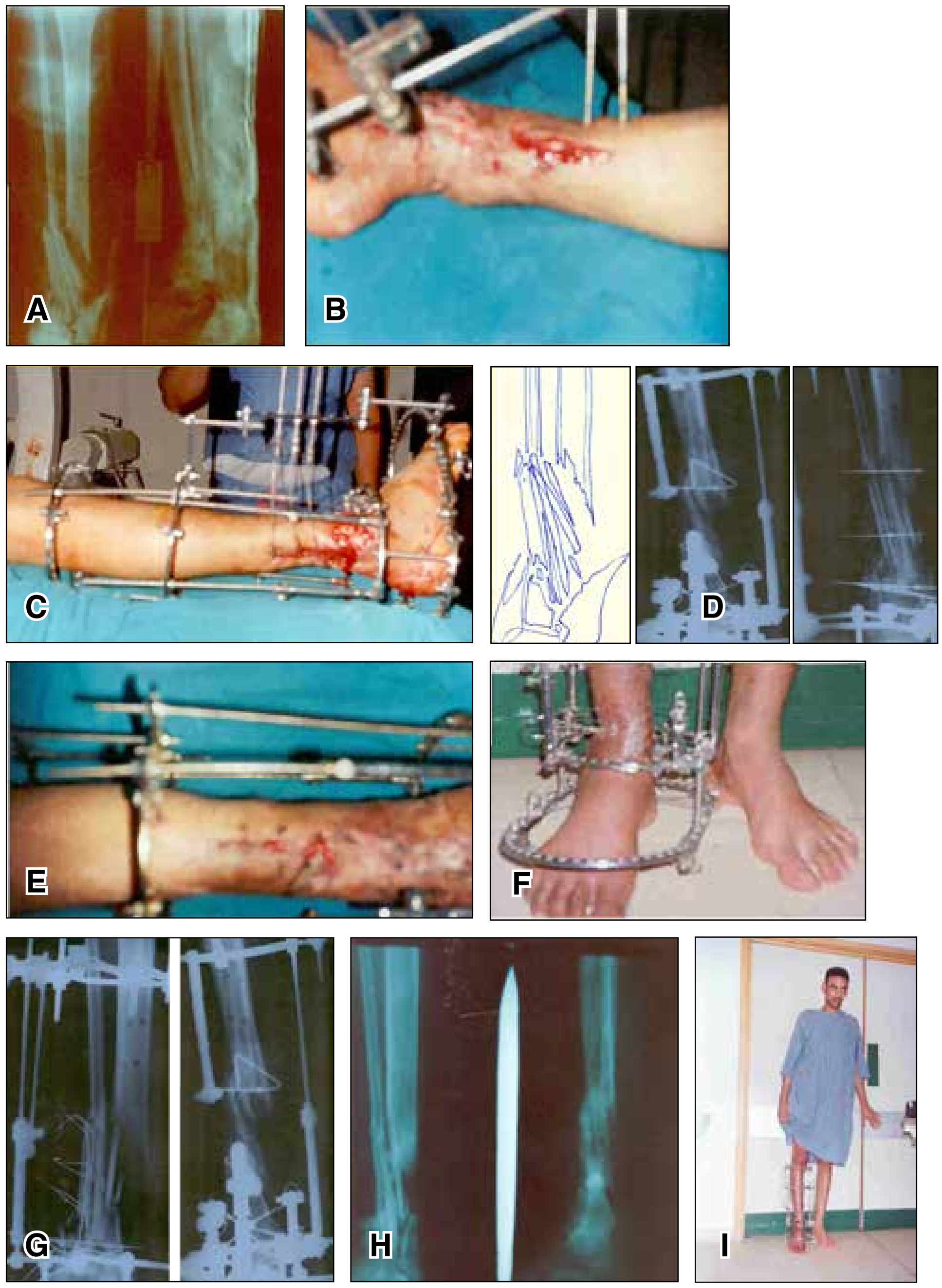

Figure 1:
A. Multiple trauma, 21 years old, male patient, had a crush foot injury, post debridement there was open fracture Grade III B. Bone shattered, comminuted, with deficient parts, and open distorted joint
B. Skin loss, crushed muscles and exposed tendons and bone. Aggressive debridement was done, no wound closure, unilateral frame application to give the chance for plastic surgery. Posterior skin release and skin grafting. Unfortunately, STSG failed.
C. A skin traction technique using Ilizarov apparatus, longitudinal and multiple perpendicular wires with hooked ends to drag the soft tissues. The skin follows the direction of traction system to close the gap
D. Left diagram of the shattered lower 1/3 leg bones, middle and right X- Rays with Ilizarov apparatus, augmented by multiple olive wires were added to reconstruct the shattered disturbed bony fragments.
E. Anterior view, soft tissue loss improved.
F. The skin traction construct was removed after 3 weeks.
G. AP and Lat views show disorganized, shattered, bony and articular fragments
H. Arranged bony fragments last follow up
I. Clinical situation at the last follow up.

Figure 2:
A. Male patient, 50yrs old, presented with comminuted infected fracture tibia fixed by uniplanar external fixation
B. Removal of external fixator, debridement of bone and soft tissues, systemic AB, local AB
C. 2nd debridement with removal of 15cm dead bone
D. Ring fixator 4 weeks later with application of olive wires through the fibula
E. 2 skin incisions at the lateral sides of the leg at the levels of proximal and distal fibular to do cortectomies.
F. During fibular transfer
G. After fibular transfer
H. Mobilized with walker while waiting graft union
I. Clinical situation after frame removal

Bibliography

1. **Aktuglu K, Erol k, Vahabi A: Ilizarov bone transport and treatment of critical-sized tibial bone defects: a narrative review.** J orthop traumatol. 2019 : 20-22. doi:10.1186/s10195-019-0527-1.

2. **Borzunov D Y, Kolchinn S N, Malkova TA : Role of the Ilizarov non-free bone plasty in the management of long bone defects and nonunion: Problems solved and unsolved.** World J orthop :2020:11(6):304-318. doi: 10.5312/wjo.v11.i6.304.

3. **Paly, Dror : Bone transport: The Ilizarov treatment for bone defects.** 1989:4(3):P80-93 .

4. **LiuY,Yushan M, Yusufu A: complications of bone transport technique using the Ilizarov method in the lower extremity: a retrospective analysis of 282consecutive case over 10years.** BMC Musculoskelet Disord: 2020:21,354 .DOI . https://doi.org/10.1186/s12891-020-03335-w.

5. **Ren, GH., Li, R., Yu, hu, Y. et al: Treatment options for infected bone defects in the lower extremities: free vascularized fibular graft or Ilizarov bone transport.** Journal of Ortho Surg Res :2020:15,439. DOI: http://doi.org/10.1186/s13018-020-01907-z.

6. **Hosny G, Fadel M: Ilizarov external fixator for open fractures of the tibial shaft.** International Orthopedic (SICOT) 2003. 27:303–306 DOI 10.1007/s00264-003-0476-3)

7. **Catgini M. Imaging techniques (the radiographic classification of bone regenerate during distraction). In Operative Principles of Ilizarov by ASAMI group.** Editors A. Bianchi Maiocchi, J. Aronson Baltimore: Williams & Wilkins; 1991. p. 53-57.

8. **C. Karger, T. Kishi, L. Schneider, F. Fitoussi, A. C. Masquelet, the French Society of Orthopaedic Surgery and Traumatology (SoFCOT). Treatment of posttraumatic bone defects by the induced membrane technique.** Orthopaedics & Traumatology: Surgery & Research Volume 98, Issue 1, February 2012, Pages 97-102

9. **S-T. J. Tsang, N. Ferreira, A. H. R. W. Simpson. The reconstruction of critical bone loss.** Bone Joint Res 2022;11(6):409–412.

10. **Ferreira N, Tanwar Y S. Systematic Approach to the Management of Post-traumatic Segmental Diaphyseal Long Bone Defects: Treatment Algorithm and Comprehensive Classification System.** Strategies in trauma and limb reconstruction. January 2021, 15(2):106-116 DOI: 10.5005/jp-journals-10080-1466

11. **Janis JE, Kwon RK, Attinger CE. The new reconstructive ladder: modifications to the traditional model.** Plast Reconstr Surg 2011;127(Suppl 1):205S–212S. DOI: 10.1097/PRS.0b013e318201271c.

12. **Morykwas MJ, Simpson J, Punger K, et al. Vacuum-assisted closure: state of basic research and physiologic foundation.** Plast Reconstr Surg 2006;117(7 Suppl):121S–126S. DOI: 10.1097/01. prs.0000225450.12593.12.

13. **McPherson EJ, Woodson C, Holtom P, et al. Periprosthetic total hip infection: outcomes using a staging system.** Clin Orthop Relat Res 2002(403):8–15. DOI: 10.1097/00003086-200210000-00003.

14. **Nauth, Aaron; Schemitsch, Emil; Norris, Brent; Nollin, Zachary DO; Watson, J. Tracy. Critical-Size Bone Defects: Is There a Consensus for Diagnosis and Treatment?** Journal of Orthopaedic Trauma 32():p S7-S11, March 2018. | DOI: 10.1097/BOT.0000000000001115

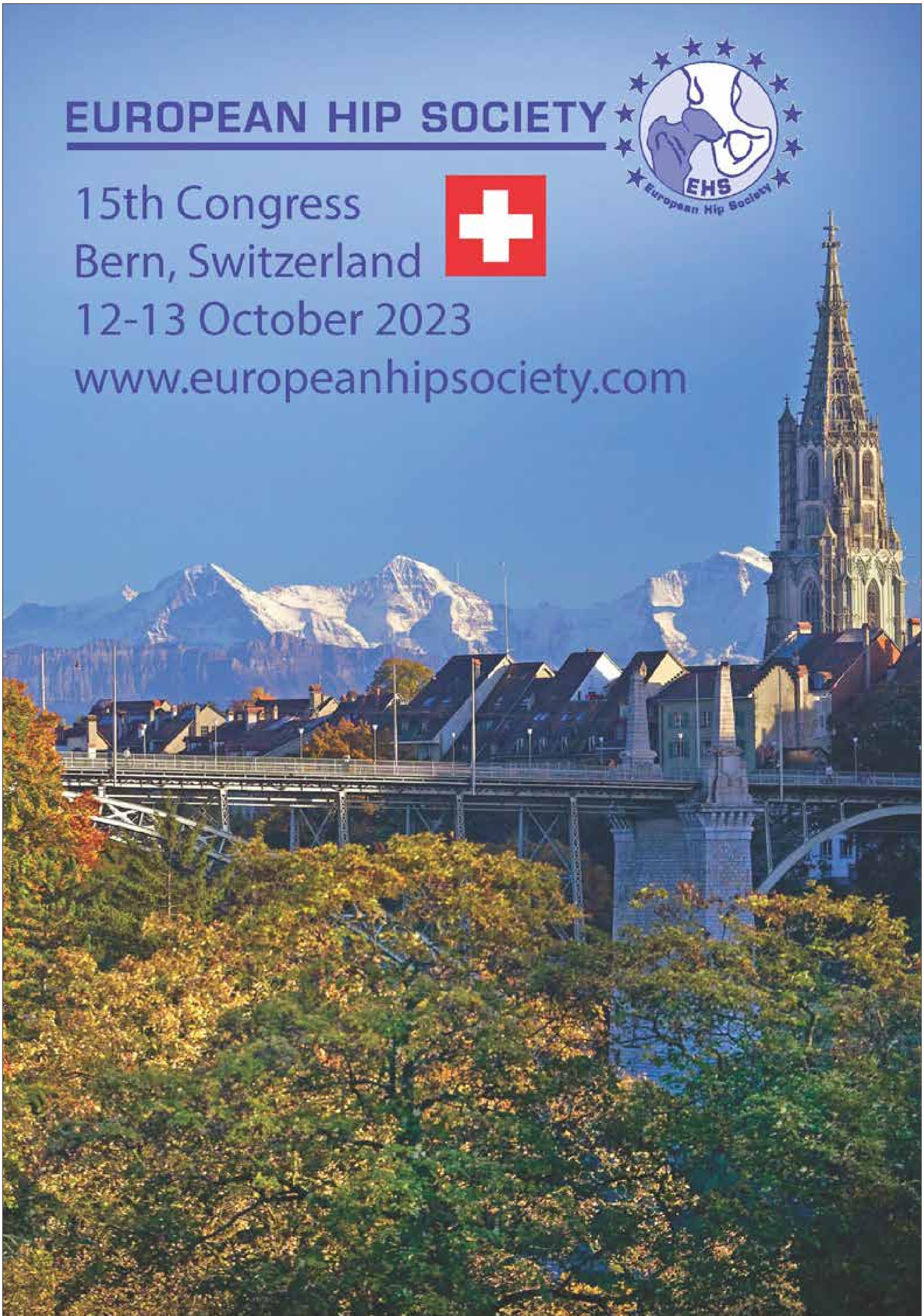
EUROPEAN HIP SOCIETY
EHS
European Hip Society
15th Congress
Bern, Switzerland
12-13 October 2023
www.europeanhipsociety.com

DECISION-MAKING PROCESS IN PERIPROSTHETIC INFECTION TREATMENT MANAGEMENT: A MULTIMODAL APPROACH

Claire PARK, Joseph BENEVENIA

Department of Orthopaedic Surgery, Rutgers New Jersey Medical School, Newark, NJ
cp906@njms.rutgers.edu

INTRODUCTION

Musculoskeletal infection remains a challenging post-operative complication amongst orthopaedic surgeons, requiring multi-specialty coordination given its potential for irreparable damage. Periprosthetic infection outcomes are driven by a multitude of factors including the causative pathogen's virulence, immunocompetency and associated comorbidities of the patient, anatomic location of the prosthesis, age of the patient, and the extent of the bone and soft tissue loss. The goal remains to eradicate the infection while salvaging the limb as much as possible without compromising the patient's functional status. Understanding the specific indications, patient characteristics, and infection parameters is crucial for selecting the most appropriate approach and optimizing outcomes. However, the most well-prepared orthopaedic surgeon has also already considered the next options in the unfortunate event if the infection persists. There is continuous debate on indications for the best methodology of treating periprosthetic infection. We provide an overview on the different options available with suggestions on when their use would be most appropriate.

THREE MAIN SURGICAL OPTIONS

Understanding the nuances and evidence supporting DAIR and staged debridement approaches is crucial in guiding clinical decision-making and optimizing the management of musculoskeletal infections. Individual patient characteristics such as infection severity, implant stability, and soft tissue condition determine whether DAIR, one-stage, or two-stage revision will be selected for initial treatment. DAIR consists of aggressive debridement of infected tissues, intravenous antibiotics, and retention of the original implant with PE insert exchange, while staged debridement involves a multistep approach with implant removal, thorough debridement, and immediate versus delayed reimplantation. There is significant variability in treatment success of preliminary management of periprosthetic infections with DAIR, one-stage, or two-stage revisions as demonstrated in Table 1.

DAIR

DAIR aims at retaining the implant with thorough debridement and irrigation with PE insert exchange. It has shown favorable results in cases of early infections, well-fixed implants, and infections caused by low-virulence organisms [1]. It is commonly indicated in situations where the infection is identified acutely (usually less than 3 weeks after symptom development), the causative pathogen has low virulence, or the patients cannot tolerate an explant either due to medical conditions or limited life expectancy. Success rates of eradicating the infection via DAIR also vary depending on the infection location with a higher success rate in a total hip replacement (60-83%) as opposed to a total knee replacement (55-70%) [1,2]. Radical debridement is one of the keys for success but has technical limitations with implants in place especially for TKA. Further risk factors that have been shown to significantly increase risk of failure after DAIR include insufficient soft tissue coverage, patients in the McPherson systemic host C group, and signs of chronic infection such as a sinus tract [3]. Additionally, DAIR has low success in immunocompromised patients with findings that risk of amputation for failed limb salvage increases by more than 6 times in such patients [4,5]. DAIR offers the potential for implant salvage, minimizing the need for additional surgeries and preserving limb function, and is associated with shorter hospital stays, reduced costs, and decreased morbidity. However, DAIR may be less effective in cases of chronic or deep-seated infections, implant loosening, or compromised soft tissues.

	Surgical Treatment	Success of infection control
HIP	DAIR	60-83%
	1-Stage	86-95%
	2 Stage (Primary)	94%
	2 Stage (Revision)	72%
	Girdlestone	90-97%
	Hip disarticulation	90%
KNEE	DAIR	55-70%
	1-Stage	86-98%
	2 Stage (Primary)	93%
	2 Stage (Revision)	82%
	Arthrodesis	84%

Table 1. Summary table of surgical treatment outcomes in periprosthetic infection

One-Stage Revision

One-stage revision removes infected components with implantation of new prosthetic components during a single operation [6]. This method is beneficial due to the fewer number of procedures required and some studies have demonstrated equal or better functional outcomes relative to those after two-stage revisions [7]. However, it is only suitable for patients that meet certain criteria including sufficient and stable soft tissue, a well-identified causative organism, and absence of sinus tracts, which may also bias functional outcome results [8,9]. Furthermore, patients with megaprostheses such as a total femur a one-stage revision might be preferred since an adequate mega spacer will immobilize the patient [10].

Two-Stage Revision

Staged revision surgery is often preferred for chronic or recurrent infections, implant loosening, and infections caused by highly virulent organisms. Although involving additional surgeries and longer treatment duration, it provides an opportunity for thorough debridement, resolution of infections, and implant exchange with improved stability. The staged approach allows for the assessment of infection control and optimization of local tissue conditions before reimplantation. Compared to single stage, two-stage revision requires prolonged hospitalization and is associated with higher rates of functional impairment and morbidity. Patients with chronic infections are at increased risk for more virulent pathogens or polymicrobial infections and usually present with not only poor-quality soft tissues, but also greater bone loss. As such, these patients are initially managed with a two-stage revision due to its greater potential for preserving bone stock than a one-stage revision [11]. Use of a mobile articulating spacer during the interim period permits early functional mobilization while maintaining joint stability and delivering local antibiotic therapy. This method has even shown to be effective utilizing large intramedullary spacers for large segmental bone defects at the knee [12].

BONE DEFECT MANAGEMENT

Extensive bone defects resulting from chronic infections are common and durable fixation remains a challenge. The introduction of porous metal wedges, cones and sleeves have significantly improved the fixation options for hips and knees. Bone transport, a technique based on the principles of distraction osteogenesis, has gained increasing attention for diaphyseal bony defects as a promising solution for managing such cases. Bone transport has demonstrated favorable outcomes however, for PJI it plays no role and will not be discussed here.

OVERVIEW OF PERIPROSTHETIC INFECTION MANAGEMENT

Patient care and counseling requires consideration of possible future reoperations and whether patients would be able to tolerate future procedures, as outlined in Figure 1. Patients who are indicated for further surgical management, regardless of the first procedure performed, the next step after failed infection control consists of a two-stage revision. If the infection continues to persist, more extensive surgical interventions are required [13]. Hip infections would require Girdlestone resection arthroplasty and very rare hip disarticulation. Unrelenting knee infection would be managed with arthrodesis, and if the infection continued to be poorly controlled, an above knee amputation (AKA). Given the high rates of morbidity and minimal improvement in functional and health status outcomes with additional limb-salvaging procedures, surgical attempts to limb-salvage should not exceed 4-6 procedures. After this many surgeries, the likely return on improvement in health outcome is diminished making amputation the best next step.

Resection Arthroplasty

Resection arthroplasty procedures follow failed attempts at DAIR and staged revisions. For complicated hip infections, the Girdlestone procedure, while not frequently utilized, has shown to be effective in controlling infection rates [14, 15]. However, functional results have not been very favorable with more than 90% of patients experiencing persistent pain and 83% are minimal community ambulators [14]. Resection arthroplasty for infected knees should be performed for wheelchair bound patients only.

Arthrodesis

Arthrodesis has a limited role in infected THA since resection arthroplasty represents the better alternative. When attempting to control TKA infections, arthrodesis can be a part of the staged revision procedures either by using this as a definitive primary procedure or after failed revision surgeries. It is usually indicated in circumstances involving an inadequate extensor mechanism, highly virulent organisms, or multiple failed attempts at limb salvaging [16]. Arthrodesis

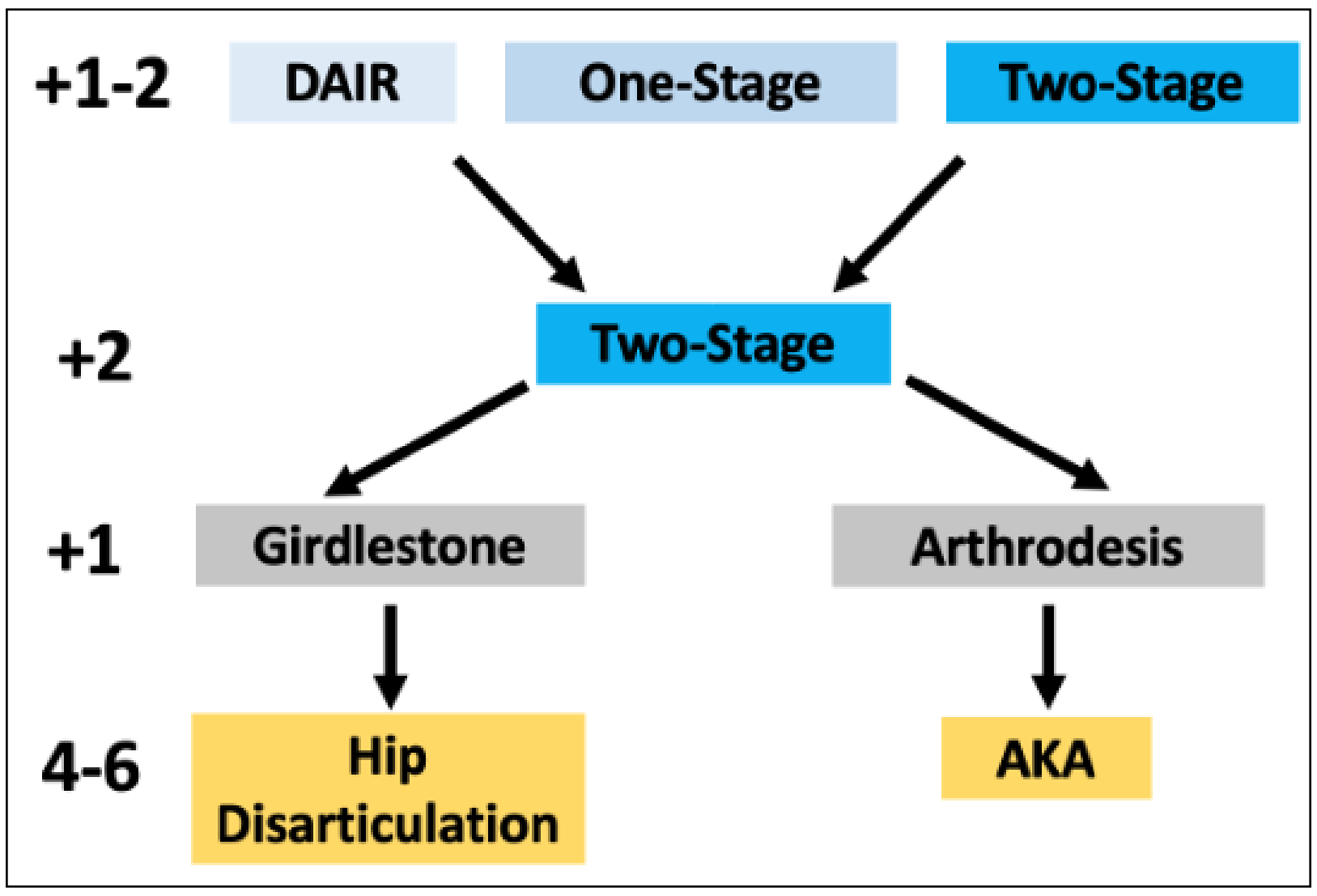

Figure 1. Overview of surgical management of periprosthetic infection

has a high success at eradicating infection with success rates over 90%, although complication rates are relatively high at 40%. It has been shown to have better functional outcomes than above-the-knee amputations [17]. However, Carr et. al determined significantly higher post-operative complication rates found in knee arthrodeses relative to above knee amputations, as summarized in Table 2 [18].

	Arthrodesis	AKA	
Post-operative Infection	14.5%	8.3%	p<0.0001
Blood transfusions	55.1%	46.8%	p<0.0001
Systemic complications	31.5%	25.9%	p<0.0001
In-patient Mortality	3.7%	2.1%	p<0.0001
Hospital length-of-stay	11 days	7 days	p<0.0001
90-day readmission rate	19.4%	16.8%	p=0.009

Table 2. Comparison of outcomes after knee arthrodesis vs.above-knee amputation after failed TKA [18]

Knee arthrodesis, common in the early 1900s, is an uncommon outcome of failed TKA. The most common reason for knee arthrodesis in modern times is failed treatment of PJI with TKA [19]. Patients with substantial metaphyseal bone loss, inadequate ligamentous restraints, multiple failed revisions, inadequate soft tissue coverage with loss of extensor mechanism and infection with virulent organisms should be considered for knee arthrodesis. Patients with failed two stage reimplantation may be candidates for arthrodesis. There are newer implants available that are considered arthrodesis endoprostheses that can bridge limited bone defects and allow for weight bearing [20]. Given the low functional outcomes of AKA versus arthrodesis, when treating a patient who requires multiple revision surgeries, earlier intervention with an arthrodesis is considered before amputation is the only viable option remaining.

Amputation

Amputations are an absolute last resort when considering treatment options for infected TKA. They are usually considered in cases of severe sepsis, unrelenting local infection with concomitant massive bone loss and uncontrollable pain [21]. Amputations are rarely considered due to the high percentage of low functional outcomes given the high energy expenditure required with at least half of patients ultimately requiring a wheelchair (22). This is why when treating a patient who requires multiple revision surgeries, earlier intervention with an arthrodesis is considered before amputation is the only viable option remaining.

In some cases, above knee amputation (AKA) for a chronically infected total knee arthroplasty is the only option. There have been several reports on the subject and various contributing factors can be identified. Severe soft-tissue loss, more than 6 reoperations, and prior flap reconstruction, correlate with the need for AKA [23]. Due to poor functional outcomes, amputations are considered an absolute last resort when considering treatment options for infected TKA [24]. Infection is the most common complication that results in the rare indication for an amputation after a TKA (0.025%) due to the higher prevalence of infection than other complications such as vascular injury and compartment syndrome (21). Similarly, hip disarticulation is a rare outcome of a chronically infected total hip arthroplasty, occurring about 0.3% of hip PJIs. Options such as Girdlestone can be chosen earlier and may eliminate the need for hip amputation (25). Patients with PJI after tumor megaprostheses are at higher risk of amputation at all levels. Jeys and Grimer found that amputation rates due to infection vary according to anatomic location of the prosthesis with the highest rates occurring at the tibia (7.8%), distal femur (2.4%), and pelvis (2.0%) [26].

Mozella found that the incidence of amputation as a result of complications from TKA was 0.41% incidence with recurrent infection responsible for 81% of cases [28]. Failure after DAIR for PJI of TKA was significantly associated by a number of factors including the presence of a sinus tract, infection due to methycillin-resistant Staph. Aureus, the immunocompromised status of the patient, treatment delays, relatively short antibiotic duration, and retention of exchangeable prosthetic components [27].

With significant surgeries such as an AKA, it is relevant to evaluate the functional and psychosocial impact on patients. Of the patients that were amputated, 44% were utilizing prostheses while 62.5% were functionally walking [28]. Ambulatory status after AKA has not shown to significantly worsen- about half of patients continuing to be nonambulatory while about a quarter remain home ambulators or community ambulators, respectively [29]. In Orfanos' retrospective analysis identified a 50% mortality rate at 5 years after AKA for PJI [30]. The majority of patients in their study (86%) were satisfied with their AKA and 42% reported that in hindisight, they would have done it sooner [30].

Currently, surgical treatment decision-making for periprosthetic infection requires careful balancing between preparing for feared and unknown outcomes while prioritizing patient safety and preservation of function. Given its ubiquity within orthopaedic surgery, we must continue to develop and improve treatment strategies and protocols to minimize infection risk. ■

Bibliography

1. **Kunutsor SK, Beswick AD, Whitehouse MR, Wylde V, Blom AW. Debridement, antibiotics and implant retention for periprosthetic joint infections: A systematic review and meta-analysis of treatment outcomes.** J Infect. 2018;77(6):479-88.

2. **Scheper H, Gerritsen LM, Pijls BG, Van Asten SA, Visser LG, De Boer MGJ. Outcome of Debridement, Antibiotics, and Implant Retention for Staphylococcal Hip and Knee Prosthetic Joint Infections, Focused on Rifampicin Use: A Systematic Review and Meta-Analysis.** Open Forum Infect Dis. 2021;8(7):ofab298.

3. **Zaruta DA, Qiu B, Liu AY, Ricciardi BF. Indications and Guidelines for Debridement and Implant Retention for Periprosthetic Hip and Knee Infection.** Curr Rev Musculoskelet Med. 2018;11(3):347-56.

4. **Jeys LM, Grimer RJ, Carter SR, Tillman RM. Periprosthetic infection in patients treated for an orthopaedic oncological condition.** J Bone Joint Surg Am. 2005;87(4):842-9.

5. **Haijie L, Dasen L, Tao J, Yi Y, Xiaodong T, Wei G. Implant Survival and Complication Profiles of Endoprostheses for Treating Tumor Around the Knee in Adults: A Systematic Review of the Literature Over the Past 30 Years.** J Arthroplasty. 2018;33(4):1275-87 e3.

6. **Kildow BJ, Springer BD, Brown TS, Lyden E, Fehring TK, Garvin KL. Long Term Results of Two-Stage Revision for Chronic Periprosthetic Hip Infection: A Multicenter Study.** J Clin Med. 2022;11(6).

7. **Klemt C, Tirumala V, Oganesyan R, Xiong L, van den Kieboom J, Kwon YM. Single-Stage Revision of the Infected Total Knee Arthroplasty Is Associated With Improved Functional Outcomes: A Propensity Score-Matched Cohort Study.** J Arthroplasty. 2021;36(1):298-304.

8. **Negus JJ, Gifford PB, Haddad FS. Single-Stage Revision Arthroplasty for Infection-An Underutilized Treatment Strategy.** J Arthroplasty. 2017;32(7):2051-5.

9. **Castellani L, Daneman N, Mubareka S, Jenkinson R. Factors Associated with Choice and Success of One- Versus Two-Stage Revision Arthroplasty for Infected Hip and Knee Prostheses.** HSS J. 2017;13(3):224-31.

10. **Holzer G, Windhager R, Kotz R. One-stage revision surgery for infected megaprostheses.** J Bone Joint Surg Br. 1997;79(1):31-5.

11. **Wichern EM, Zielinski MR, Ziemba-Davis M, Meneghini RM. Contemporary 2-Stage Treatment of Periprosthetic Hip Infection with Evidence-Based Standardized Protocols Yields Excellent Results: Caveats and Recommendations.** J Arthroplasty. 2020;35(10):2983-95.

12. **Ippolito JA, Thomson JE, Rivero SM, Beebe KS, Patterson FR, Benevenia J. Management of Large Segmental Bone Defects at the Knee With Intramedullary Stabilized Antibiotic Spacers During Two-Stage Treatment of Endoprosthetic Joint Infection.** J Arthroplasty. 2021;36(6):2165-70.

13. **Fagotti L, Tatka J, Salles MJC, Queiroz MC. Risk Factors and Treatment Options for Failure of a Two-Stage Exchange.** Curr Rev Musculoskelet Med. 2018;11(3):420-7.

14. **Vincenten CM, Den Oudsten BL, Bos PK, Bolder SBT, Gosens T. Quality of life and health status after Girdlestone resection arthroplasty in patients with an infected total hip prosthesis.** J Bone Jt Infect. 2019;4(1):10-5.

15. **Kantor GS, Osterkamp JA, Dorr LD, Fischer D, Perry J, Conaty JP. Resection arthroplasty following infected total hip replacement arthroplasty.** J Arthroplasty. 1986;1(2):83-9.

16. **Mabry TM, Jacofsky DJ, Haidukewych GJ, Hanssen AD. Comparison of intramedullary nailing and external fixation knee arthrodesis for the infected knee replacement.** Clin Orthop Relat Res. 2007;464:11-5.

17. **Wang M, Liu T, Xu C, Liu C, Li B, Lian Q, et al. 3D-printed hemipelvic prosthesis combined with a dual mobility bearing in patients with primary malignant neoplasm involving the acetabulum: clinical outcomes and finite element analysis.** BMC Surg. 2022;22(1):357.

18. **Carr JB, 2nd, Werner BC, Browne JA. Trends and Outcomes in the Treatment of Failed Septic Total Knee Arthroplasty: Comparing Arthrodesis and Above-Knee Amputation.** J Arthroplasty. 2016;31(7):1574-7.

19. **Conway JD, Mont MA, Bezwada HP. Arthrodesis of the knee.** J Bone Joint Surg Am. 2004;86(4):835-48.

20. **Luyet A, Steinmetz S, Gallusser N, Roche D, Fischbacher A, Tissot C, et al. Fusion rate of 89% after knee arthrodesis using an intramedullary nail: a mono-centric retrospective review of 48 cases.** Knee Surg Sports Traumatol Arthrosc. 2023;31(4):1299-306.

21. **Mousavian A, Sabzevari S, Ghiasi S, Shahpari O, Razi A, Ebrahimpour A, et al. Amputation as a Complication after Total Knee Replacement, is it a Real Concern to be Discussed?: A Systematic Review.** Arch Bone Jt Surg. 2021;9(1):9-21.

22. **Traugh GH, Corcoran PJ, Reyes RL. Energy expenditure of ambulation in patients with above-knee amputations.** Arch Phys Med Rehabil. 1975;56(2):67-71.

23. **Khanna V, Tushinski DM, Soever LJ, Vincent AD, Backstein DJ. Above knee amputation following total knee arthroplasty: when enough is enough.** J Arthroplasty. 2015;30(4):658-62.

24. **Sierra RJ, Trousdale RT, Pagnano MW. Above-the-knee amputation after a total knee replacement: prevalence, etiology, and functional outcome.** J Bone Joint Surg Am. 2003;85(6):1000-4.

25. **Schwartz AJ, Trask DJ, Bews KA, Hanson KT, Etzioni DA, Habermann EB. Hip Disarticulation for Periprosthetic Joint Infection: Frequency, Outcome, and Risk Factors.** J Arthroplasty. 2020;35(11):3269-73 e3.

26. **Jeys LM, Grimer RJ, Carter SR, Tillman RM. Risk of amputation following limb salvage surgery with endoprosthetic replacement, in a consecutive series of 1261 patients.** Int Orthop. 2003;27(3):160-3.

27. **Qasim SN, Swann A, Ashford R. The DAIR (debridement, antibiotics and implant retention) procedure for infected total knee replacement - a literature review.** SICOT J. 2017;3:2.

28. **Mozella AP, da Palma IM, de Souza AF, Gouget GO, de Araujo Barros Cobra HA. Amputation after failure or complication of total knee arthroplasty: prevalence, etiology and functional outcomes.** Rev Bras Ortop. 2013;48(5):406-11.

29. **George J, Newman JM, Caravella JW, Klika AK, Barsoum WK, Higuera CA. Predicting Functional Outcomes After Above Knee Amputation for Infected Total Knee Arthroplasty.** J Arthroplasty. 2017;32(2):532-6.

30. **Orfanos AV, Michael RJ, Keeney BJ, Moschetti WE. Patient-reported outcomes after above-knee amputation for prosthetic joint infection.** Knee. 2020;27(3):1101-5.